AGAPLESION
Unsere Werte verbinden

Deutsche Rhythmustage 2020

Arrhythmogenic Cardiomyopathy

15. Oktober 2020

AGAPLESION DIAKONIE KLINIKEN KASSEL

Priv.-Doz. Dr. med. Ole-A. Breithardt
FESC, MHBA

Potentielle Interessenskonflikte

AGAPLESION
Unsere Werte verbinden

- Mitglied der folgenden Standesorganisationen:
  DGK, DGIM, DGIIN, DEGUM, ESC, EACVI, EACPI, EHRA, ALKK, VLK

- Editorial Board Member:
  European Heart Journal, EHJ Cardiovascular Imaging

- Vortragshonorare (letzte 2 Jahre, jeweils <5k):
  Pfizer, Bayer, Daiichi Sankyo

- Aktienanteile (jeweils <10k):
  Bayer, Medtronic, Fresenius

Arrhythmogenic **Right Ventricular** Cardiomyopathy (ARVC)

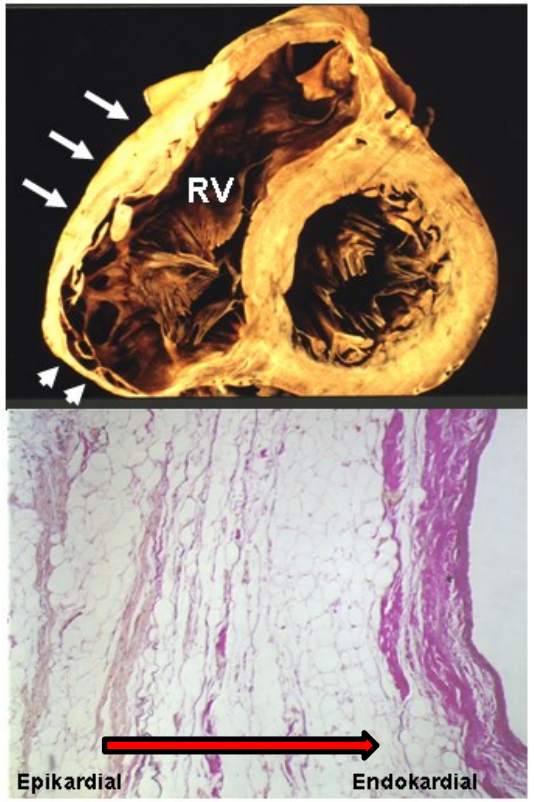

Wichter T et al. Internist. 2004:45:1125-35

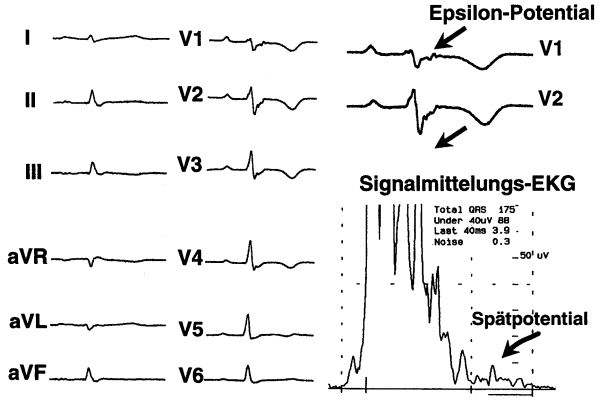

Wichter T et al. Z Kardiol. 1991

cellular damage /
myocardial necrosis

⇩

fibro-fatty replacement
epi ➔ endo

⇩ ⇩

RV remodelling
RV dilatation & failure

electrical instability
slowed conduction
& dispersed refractoriness

⇩ ⇩

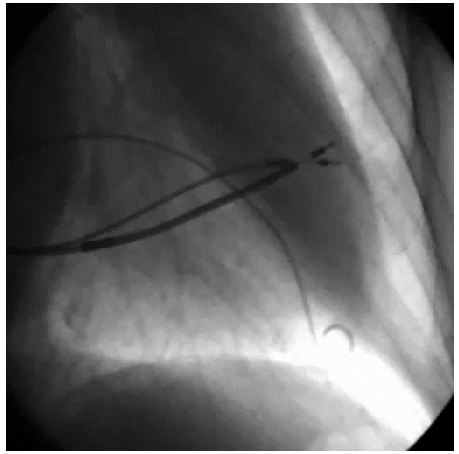

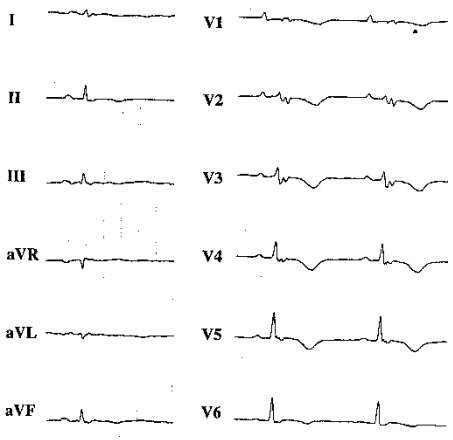

© Wichter-T/Breithardt-G, UK Münster

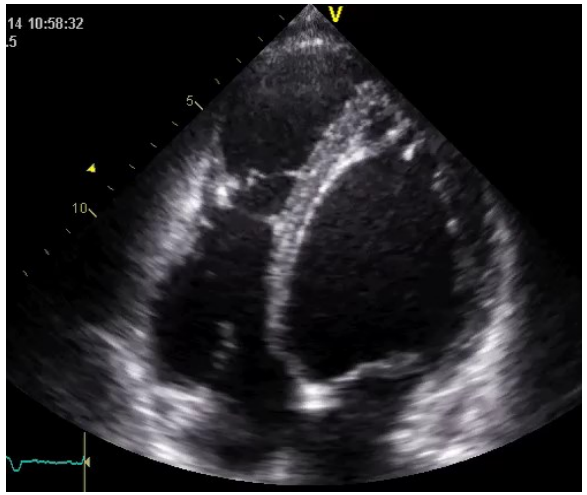

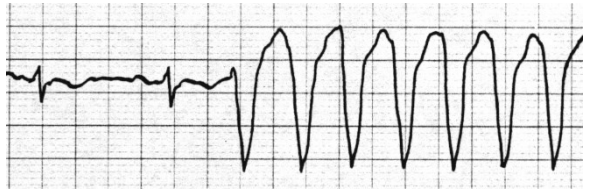

men/women 2:1
Prevalence ~1:1000
(north. Italy 4:1000)

The Road from *ARVC* ....

Right Ventricular Dysplasia: A Report of 24 Adult Cases — 1982

Frank I. Marcus, M.D., Guy H. Fontaine, M.D., Gerard Guiraudon, M.D., Robert Frank, M.D., Jean L. Laurenceau, M.D., Christine Malergue, M.D., and Yves Grosgogeat, M.D.

SUMMARY Right ventricular dysplasia is characterized by an abnormality in the development of part of the right ventricular musculature. Patients with right ventricular dysplasia may present with ventricular tachycardia, supraventricular arrhythmias, right-heart failure or asymptomatic cardiomegaly. Twenty-two adult patients with right ventricular dysplasia who had recurrent ventricular tachycardia were seen during a 7-year period. The male/female ratio was 2.7:1. The mean age at the time of hospitalization was 39 years. All but one of the patients had ventricular tachycardia of a left bundle branch block configuration. With few exceptions, the T waves were inverted over the right precordial leads. The heart was usually enlarged and the pulmonary vasculature was usually normal. In six patients who had two-dimensional echocardiograms, all showed increased right ventricular diastolic dimensions. All patients had right ventricular angiography; the diagnosis of right ventricular dysplasia was substantiated during surgery in 12 patients and at autopsy in another. Two other patients who did not have arrhythmias had right ventricular dysplasia diagnosed by right- and left-heart angiography.

Our unique experience, when combined with a literature review of 34 adult cases, permits a composite clinical profile of this condition in the adult.

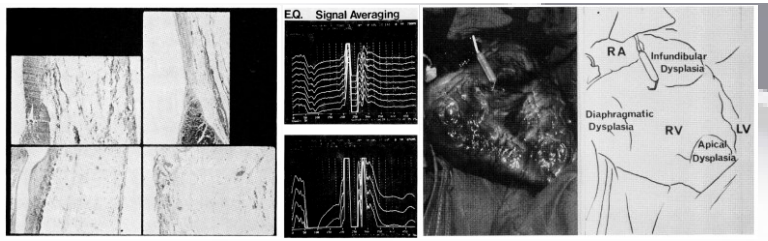

Marcus-FI et al., Circulation 1982

Early observations 1978/1982

...to *ACM*

Diagnostic Criteria („Task Force")

Br Heart J 1994;71:215–218 215

CRITERIA

Diagnosis of arrhythmogenic right ventricular dysplasia/cardiomyopathy — 1994

William J McKenna, Gaetano Thiene, Andrea Nava, Fabrice Fontaliran, Carina Blomstrom-Lundqvist, Guy Fontaine, Fulvio Camerini on behalf of the Task Force of the Working Group Myocardial and Pericardial Disease of the European Society of Cardiology and of the Scientific Council on Cardiomyopathies of the International Society and Federation of Cardiology, supported by the Schoepfer Association

Criteria for diagnosis of right ventricular dysplasia

I Global and/or regional dysfunction [illegible] tural alterations[17–23]*

MAJOR
Severe dilatation and reduction of right [illegible] fraction with no (or only mild) LV imp[illegible]
Localised right ventricular aneurysms [illegible] areas with diastolic bulging)
Severe segmental dilatation of the ri[illegible]

MINOR
Mild global right ventricular dilat[illegible] reduction with normal left ventri[illegible]
Mild segmental dilatation of the [illegible]
Regional right ventricular hypokines[illegible]

II Tissue characterisation of walls

MAJOR
Fibrofatty replacement of myocardium on endomyocardial biopsy

III Repolarisation abnormalities

MINOR
Inverted T waves in right precordial leads (V2 and V3) (people aged more than 12 yr; in absence of right bundle branch block)

IV Depolarisation/conduction abnormalities

MAJOR
Epsilon waves or localised prolongation (>110 ms) of the [illegible] complex in right precordial leads (V1–V3)

[illegible] averaged ECG)

[illegible] tycardia [illegible] exercise

[illegible] n 1000/24 h)

MAJOR
Familial [illegible] or surgery

MINOR
Familial history of premature [illegible] death (<35 yr) due to suspected right ventricular dysplasia
Familial history (clinical diagnosis based on present criteria)

Two major criteria
or
One major plus two minor criteria
or
Four minor criteria

*Detected by echocardiography, angiography, magnetic resonance imaging, or radionuclide scintigraphy. ECG, electrocardiogram; LV, left ventricle.

Mc Kenna-WJC et al., British Heart Journal 1994

Genetics & advanced Imaging (CMR)

Clinical and Genetic Characterization of Families With Arrhythmogenic Right Ventricular Dysplasia/Cardiomyopathy Provides Novel Insights Into Patterns of Disease Expression — 2007

Srijita Sen-Chowdhry, MA, MBBS, MRCP; Petros Syrris, PhD; Deirdre Ward, MBBS, MRCPI; Angeliki Asimaki, BSc; Elias Sevdalis, MD; William J. McKenna, MD, DSc, FRCP

Background—According to clinical-pathological correlation studies, the natural history of arrhythmogenic right ventricular dysplasia/cardiomyopathy is purported to progress from localized to global right ventricular dysfunction, followed by left ventricular (LV) involvement and biventricular pump failure. The inevitable focus on sudden death victims and transplant recipients may, however, have created a skewed perspective of a genetic disease. We hypothesized that unbiased representation of the spectrum of disease expression in arrhythmogenic right ventricular dysplasia/cardiomyopathy would require in vivo assessment of families in a genetically heterogeneous population.

Methods and Results—A cohort of 200 probands and relatives satisfying task force or modified diagnostic criteria for arrhythmogenic right ventricular dysplasia/cardiomyopathy underwent comprehensive clinical evaluation. Desmosomal mutations were identified in 39 individuals from 20 different families. Indices of structural severity correlated with advancing age and were increased in long-term endurance athletes. Fulfillm[illegible] ed phenotypically mild disease, whereas asymptomatic status did not. In >80%, [illegible] /or gadolinium-enhanced cardiovascular magnetic resonance were suggestive of LV inv[illegible] en was marked among individuals with chain-termination mutations and/or desmoplak[illegible] se expression were identified: (1) *classic*, with isolated right ventricular disease or I[illegible] ith significant right ventricular impairment; (2) *left dominant*, with early and promine[illegible] ly mild right-sided disease; and (3) *biventricular*, characterized by parallel involvement of both ventricles.

Conclusions—LV involvement in arrhythmogenic right ventricular dysplasia/cardiomyopathy may precede the onset of significant right ventricular dysfunction. Recognition of disease variants with early and/or predominant LV involvement supports adoption of the broader term arrhythmogenic cardiomyopathy. (***Circulation*. 2007;115:1710-1720.**)

Key Words: arrhythmia ■ cardiomyopathy ■ death, sudden ■ genetics ■ electrocardiograpy ■ imaging

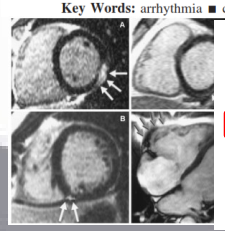

Individuals with and without mutations in each of the 3 main desmosomal genes were subsequently compared (online Data Supplement Table IV). Results were unremarkable for the plakophilin-2 and desmoglein-2 subgroups. However, carriers of desmoplakin defects had increased LVEDV, reduced LVEF, higher LVlesion scores, and greater prevalence of notable ventricular arrhythmia, nonsustained VT, lateral T-wave inversion, ventricular arrhythmia of RBBB morphology, and left-dominant disease expression than those who did not. A cross-

Sen-Chordhry-S et al., Circulation 2007

AGAPLESION
Unsere Werte verbinden

Arrhythmogenic Cardiomyopathy (ACM)

Dominant-right (ARVC)

- morpho-functional and/or structural RV criteria

-no morpho-functional and/or structural LV criteria

Corrado-D et al., Int J Cardiol 2020 (epub)

Arrhythmogenic Cardiomyopathy

Genetic Background

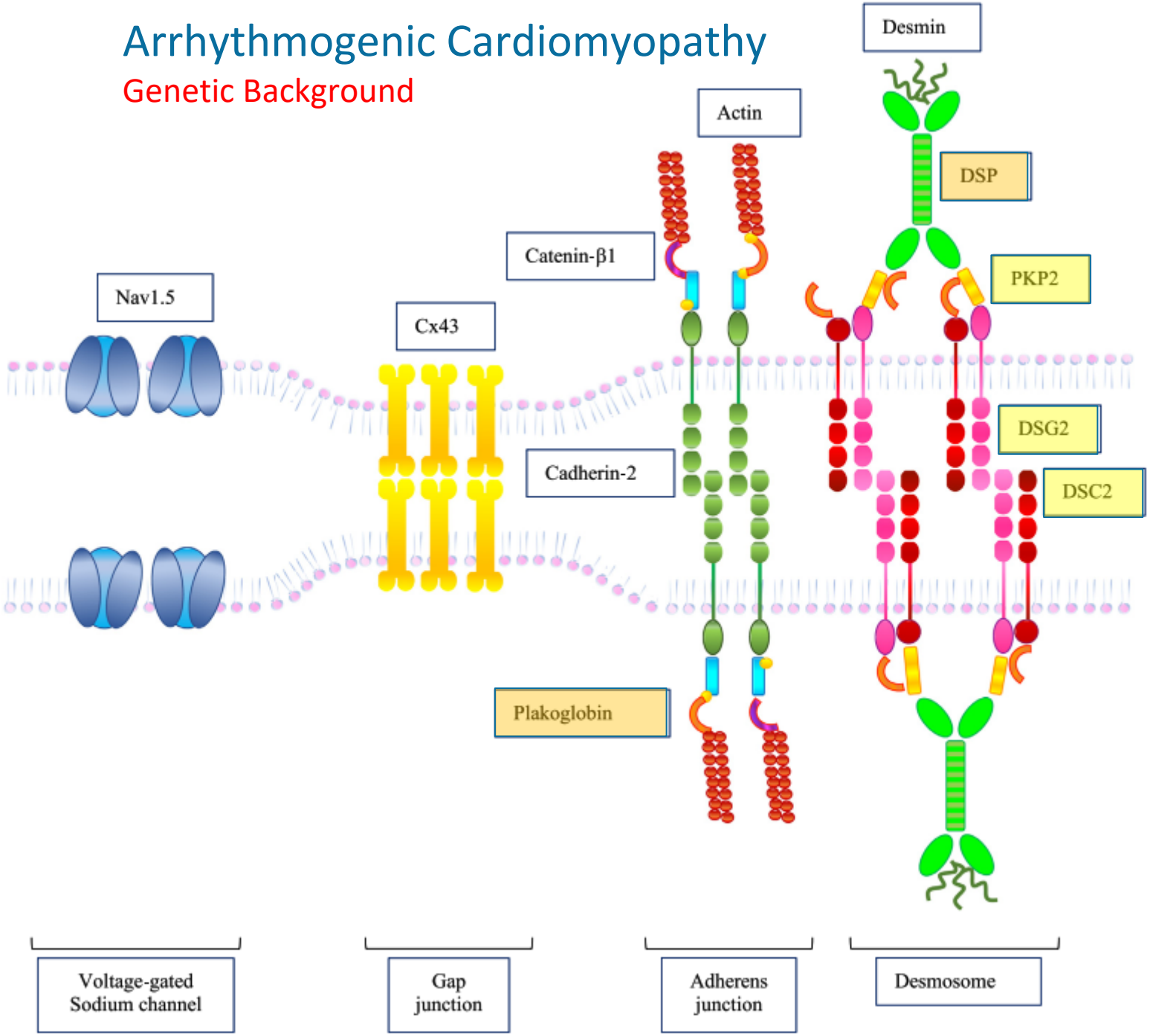

- Disease of the intercalated disc
  - end-to-end contact of cardiac myocytes
  - mechanical and electrical coupling
- 60% of ACM pts carry a genetic pathogenic variant, mostly *autosomal dominant*
- Majority of mutations affect the *desmosome*:
  - **plakophilin-2 (PKP2)**
  - desmoglein-2 (DSG2)
  - desmocollin-2 (DSC2)
  - junction plakoglobin (JUP)
  - desmoplakin (DSP)
- Non-desmosomal genes include…
  transmembrane proteine 43 (TMEM43), desmin (DES), phospholambdan (PLB), N-cadherin (CDH2), sodium volt-gated channel alpha subunit 5 (SCN5A), titin (TTN), transforming growth factor 3 beta (TGF3ß)

Costa-S et al., Trends CV Medicine 2020 (epub)

Arrhythmogenic Cardiomyopathy

Two **Autosomal Recessive** Variants

AGAPLESION
Unsere Werte verbinden

Naxos-Disease

first description 1986 by N.Protonotarios et al. in a family on the Greek island Naxos (9 cases in 4 families)

wooly hair, palmoplantar keratoderma, A**R**VC

plakoglobin mutations

RV

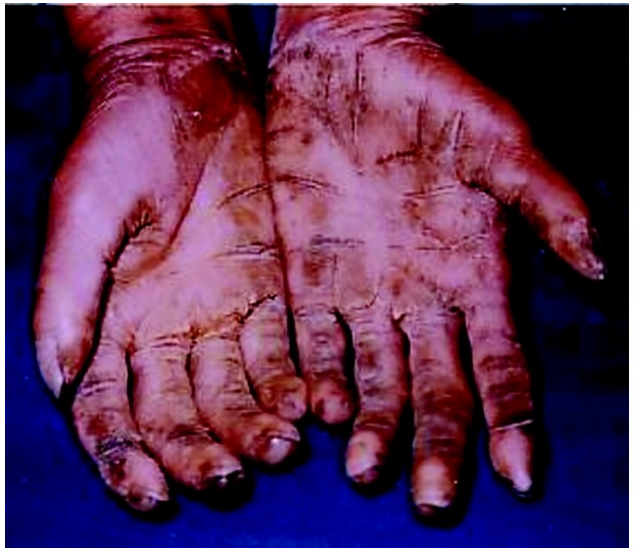

Sajeev-CG et al., Circulation 2006

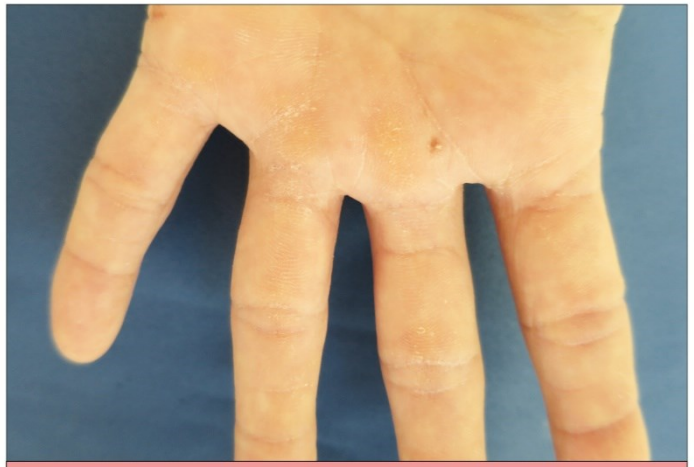

Abb. 1: Palmare Hyperkeratose der 43-jährigen Patientin mit Carvajal-Syndrom

Abb. 2: Wolliges Haar der 43-jährigen Patientin mit Carvajal-Syndrom

Stöllberger-B et al., Int J Cardiol 2016/ UiM 01/2016

Carvajal-Syndrome

first description mid 90s by E. Carvajal-Huerta, Ecuador

wooly hair, palmoplantar keratoderma
early onset **LV** DCM/NCCM

desmoplakin mutations

LV

2010

AGAPLESION
Unsere Werte verbinden

EUROPEAN SOCIETY OF CARDIOLOGY®

European Heart Journal (2010) **31**, 806–814
doi:10.1093/eurheartj/ehq025

SPECIAL REPORT



Frank I. Marcus

Diagnosis of arrhythmogenic right ventricular cardiomyopathy/dysplasia

Proposed Modification of the Task Force Criteria

Frank I. Marcus[1]* Chair, William J. McKenna[2] Co-Chair, Duane Sherrill[1], Cristina Basso[3], Barbara Bauce[3], David A. Bluemke[4], Hugh Calkins[5], Domenico Corrado[3], Moniek G.P.J. Cox[6], James P. Daubert[7], Guy Fontaine[10], Kathleen Gear[1], Richard Hauer[6], Andrea Nava[3], Michael H. Picard[11], Nikos Protonotarios[13], Jeffrey E. Saffitz[12], Danita M. Yoerger Sanborn[11], Jonathan S. Steinberg[9], Harikrishna Tandri[5], Gaetano Thiene[3], Jeffrey A. Towbin[14], Adalena Tsatsopoulou[13], Thomas Wichter[15], and Wojciech Zareba[8]

[1]University of Arizona, Tucson, AZ; [2]The Heart Hospital, London, United Kingdom; [3]University of Padua Medical School, Padua, Italy; [4]National Institutes of Health, Clinical Center, Bethesda; [5]Johns Hopkins Hospital, Baltimore, MD; [6]University Medical Center Utrecht, Utrecht, The Netherlands; [7]Strong Memorial Hospital, Rochester, NY; [8]University of Rochester Medical Center, Rochester, NY; [9]St. Luke's-Roosevelt Hospital Center, New York, NY; [10]Hopital La Salpetriere, Paris, France; [11]Massachusetts General Hospital, Boston, MA; [12]Beth Israel Deaconess Medical Center, Boston, MA; [13]Yannis Protonotarios Medical Centre, Hora Naxos, Greece; [14]Cincinnati Children's Hospital, Cincinnati, OH; and [15]Marienhospital Osnabrück, Osnabrück, Germany

Online publish-ahead-of-print 19 February 2010

Arrhythmogenic Cardiomyopathy

Modified Task Force Criteria

I. Global or regional dysfunction and structural alterations

II. Tissue characterization of wall

III. Repolarization abnormalities

IV. Depolarization/conduction abnormalities

V. Arrhythmias

VI. Family History

Imaging

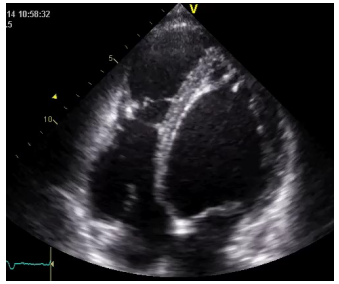

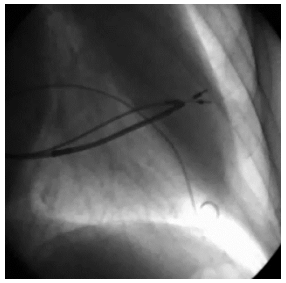

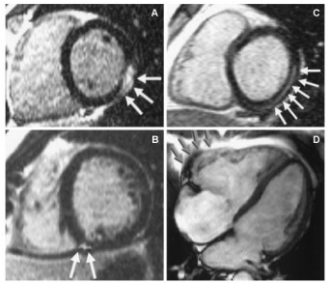

Biopsy

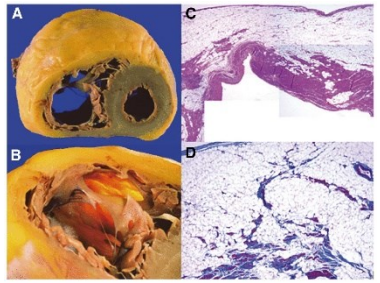

ECG

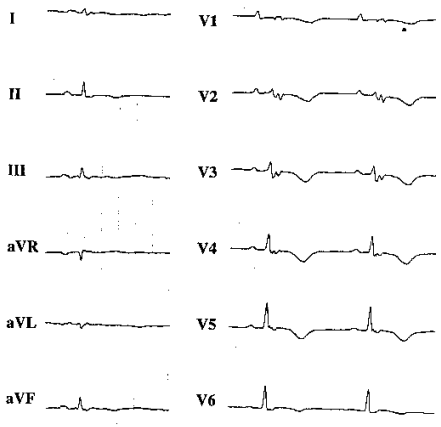

Holter

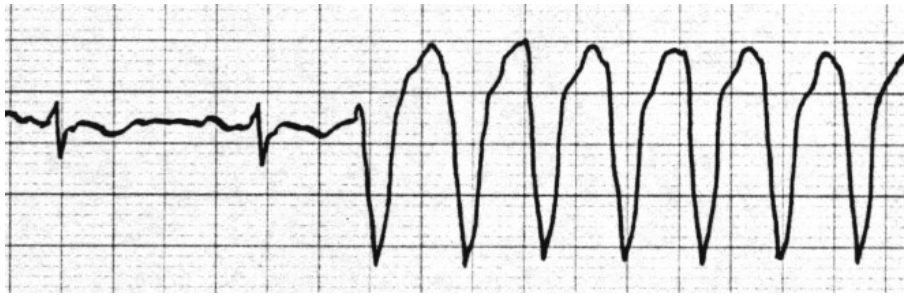

Genetic Testing

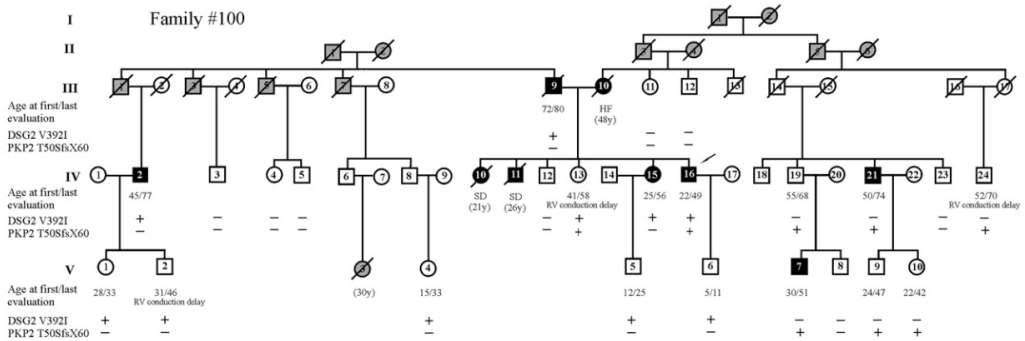

Category	Right ventricle (upgraded 2010 ITF diagnostic criteria)	Left ventricle (new diagnostic criteria)
I. Morpho-functional ventricular abnormalities	*By echocardiography, CMR or angiography:* *Major* • Regional RV akinesia, dyskinesia, or bulging *plus* one of the following: - global RV dilatation (increase of RV EDV according to the imaging test specific nomograms) - global RV systolic dysfunction (reduction of RV EF according to the imaging test specific nomograms) *Minor* • Regional RV akinesia, dyskinesia or aneurysm of RV free wall	*By echocardiography, CMR or angiography:Minor* • Global LV systolic dysfunction (depression of LV EF or reduction of echocardiographic global longitudinal strain), with or without LV dilatation (increase of LV EDV according to the imaging test specific nomograms for age, sex, and BSA) *Minor* • Regional LV hypokinesia or akinesia of LV free wall, septum, or both
II. Structural myocardial abnormalities	*By CE-CMR:Major* • Transmural LGE (stria pattern) of ≥1 RV region(s) (inlet, outlet, and apex in 2 orthogonal views) *By EMB (limited indications):Major* • Fibrous replacement of the myocardium in ≥1 sample, with or without fatty tissue	*By CE-CMR:Major* • LV LGE (stria pattern) of ≥1 Bull's Eye segment(s) (in 2 orthogonal views) of the free wall (subepicardial or midmyocardial), septum, or both (excluding septal junctional LGE)
III. Repolarization abnormalities	*Major* • Inverted T waves in right precordial leads (V_1,V_2, and V_3) or beyond in individuals with complete pubertal development (in the absence of complete RBBB) *Minor* • Inverted T waves in leads V1 and V2 in individuals with completed pubertal development (in the absence of complete RBBB) • Inverted T waves in V1,V2,V3 and V4 in individuals with completed pubertal development in the presence of complete RBBB.	*Minor* • Inverted T waves in left precordial leads (V_4-V_6) (in the absence of complete LBBB)
IV. Depolarization abnormalities	*Minor* • Epsilon wave (reproducible low-amplitude signalsbetween end of QRS complex to onset of the T wave) in the right precordial leads (V1 to V3) • Terminal activation duration of QRS ≥55 ms measured from the nadir of the S wave to the end of the QRS, including R', in V1, V2, or V3 (in the absence of complete RBBB)	*Minor* • Low QRS voltages (<0.5 mV peak to peak) in limb leads (in the absence of obesity, emphysema, or pericardial effusion)
V. Ventricular arrhythmias	*Major* • Frequent ventricular extrasystoles (>500 per 24 h), non-sustained or sustained ventricular tachycardia of LBBB morphology *Minor* • Frequent ventricular extrasystoles (>500 per 24 h), non-sustained or sustained ventricular tachycardia of LBBB morphology with inferior axis ("RVOT pattern")	*Minor* • Frequent ventricular extrasystoles (>500 per 24 h), non-sustained or sustained ventricular tachycardia with a RBBB morphology (excluding the "fascicular pattern")
VI. Family history/genetics	*Major* • ACM confirmed in a first-degree relative who meets diagnostic criteria • ACM confirmed pathologically at autopsy or surgery in a first degree relative • Identification of a pathogenic or likely pathogenetic ACM mutation in the patient under evaluation *Minor* • History of ACM in a first-degree relative in whom it is not possible or practical to determine whether the family member meets diagnostic criteria • Premature sudden death (<35 years of age) due to suspected ACM in a first-degree relative • ACM confirmed pathologically or by diagnostic criteria in a second-degree relative	

ACM = arrhythmogenic cardiomyopathy; BSA = body surface area; EDV = end diastolic volume; EF = ejection fraction; ITF = International Task Force; LBBB = left bundle-branch block; LGE = late gadolinium enhancement; LV = left ventricle; RBBB = right bundle-branch block; RV = right ventricle; RVOT = right ventricular outflow tract.

2020

„Padua"-Criteria

(proposal Corrado-D et al.)

Domenico Corrado

New:

- specific *criteria for LV phenotype*
- CMR *LGE* patterns
- *additional ECG* criteria
  ➔ low voltage limb leads

Corrado-D et al., Int J Cardiol 2020 (epub)

AGAPLESION
Unsere Werte verbinden

Genetic Testing

Who

For individuals and descendants with either a clinical or necropsy diagnosis of ACM, genetic testing of the established ACM-susceptibility genes is recommended (COR I, LOE C-EO).*

*Cascade Family Screening

How

For genetic testing of the established ACM-susceptibility genes, comprehensive analysis of all established genes with full coverage is recommended (COR I, LOE C-EO).

The interpretation of a cardiac genetic test by a team of providers with expertise in genetics and cardiology can be useful (COR IIa, LOE C-EO).

Towbin-JA et al., HRS Consensus ARC, Heart Rhythm 2019

Genetic Diagnosis

Clinical Relevance for Family Members

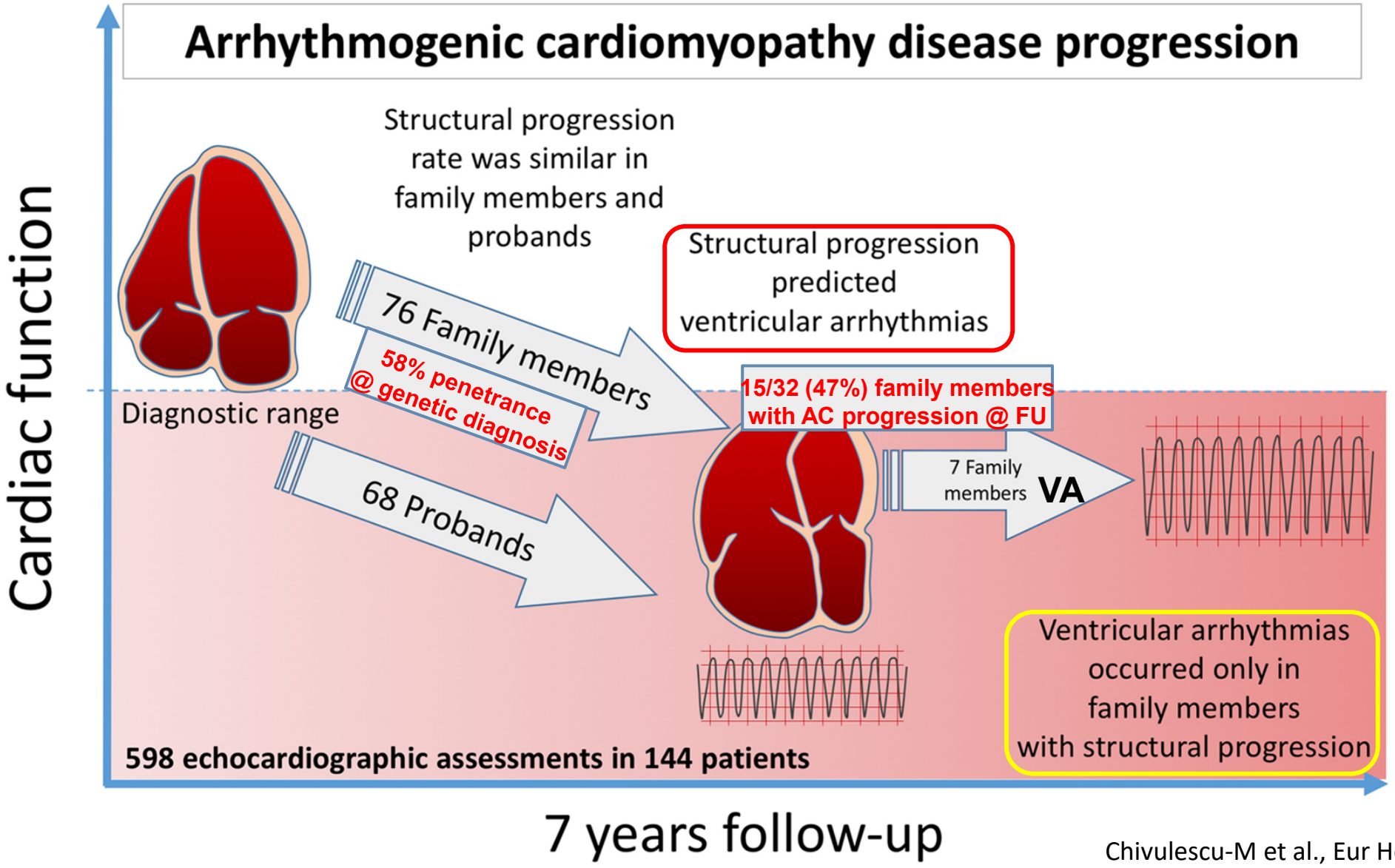

Chivulescu-M et al., Eur Heart J 2019

Col du Tourmalet 21.07.2003

Association of **Exercise History & Diagnosis** of ARVC/ARC

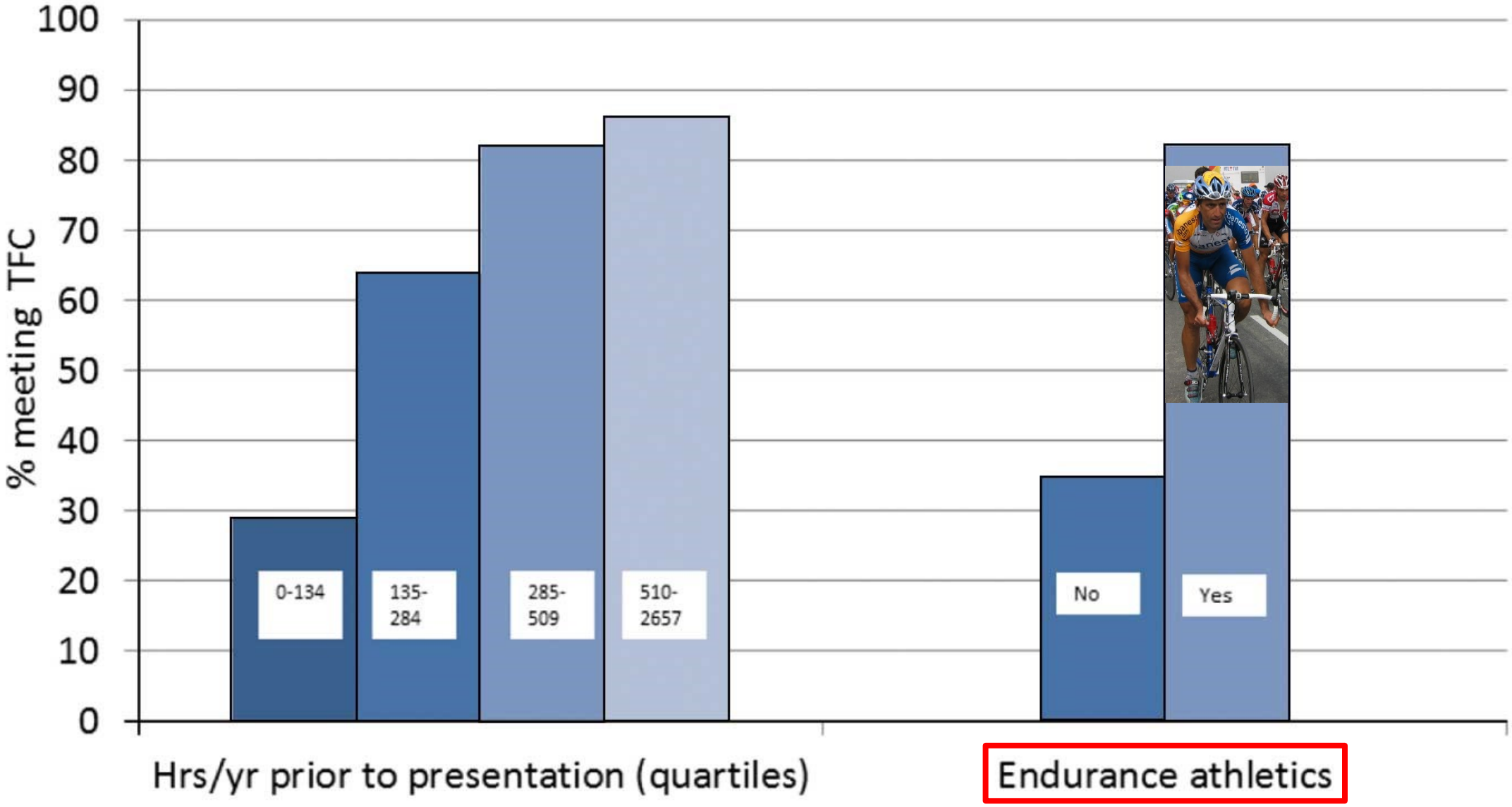

James-CA et al., J Am Coll Cardiol 2013
Calkins-H, Circulation J 2015; 901-913

Harmful Effects of Exercise in ARC

Lie-Ø et al., JACC EP 2018

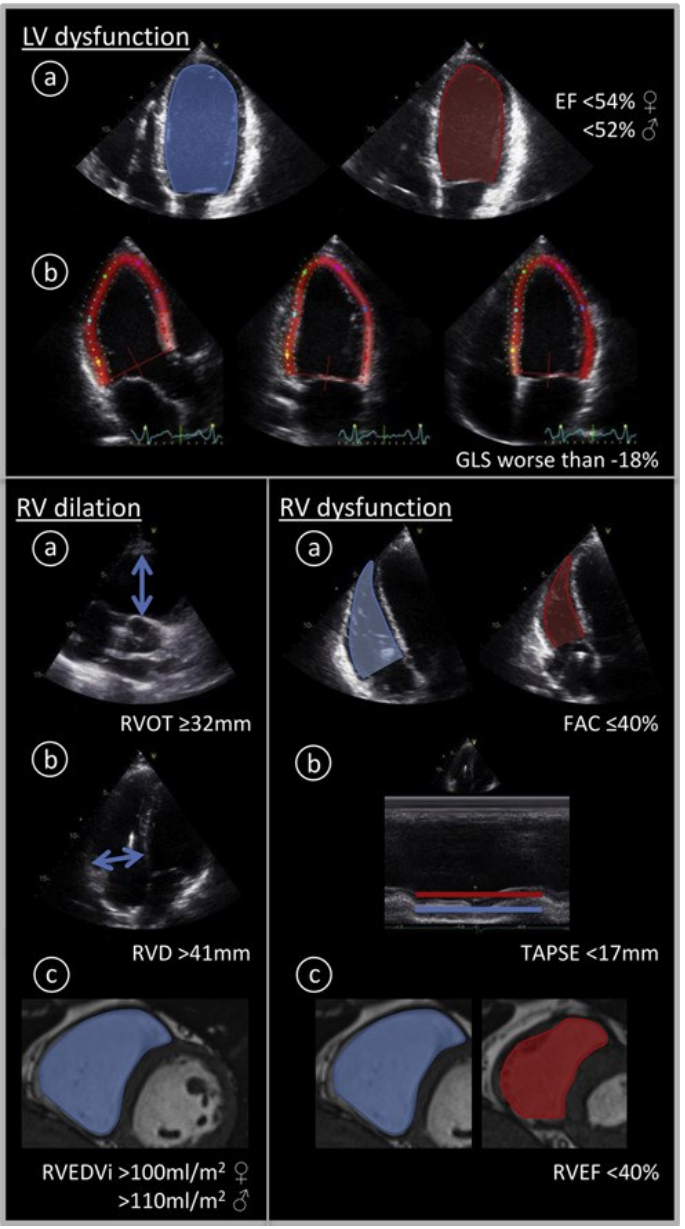

n= 173 – 83/173 with ventricular arrhythmias

> 2.5 hours / week

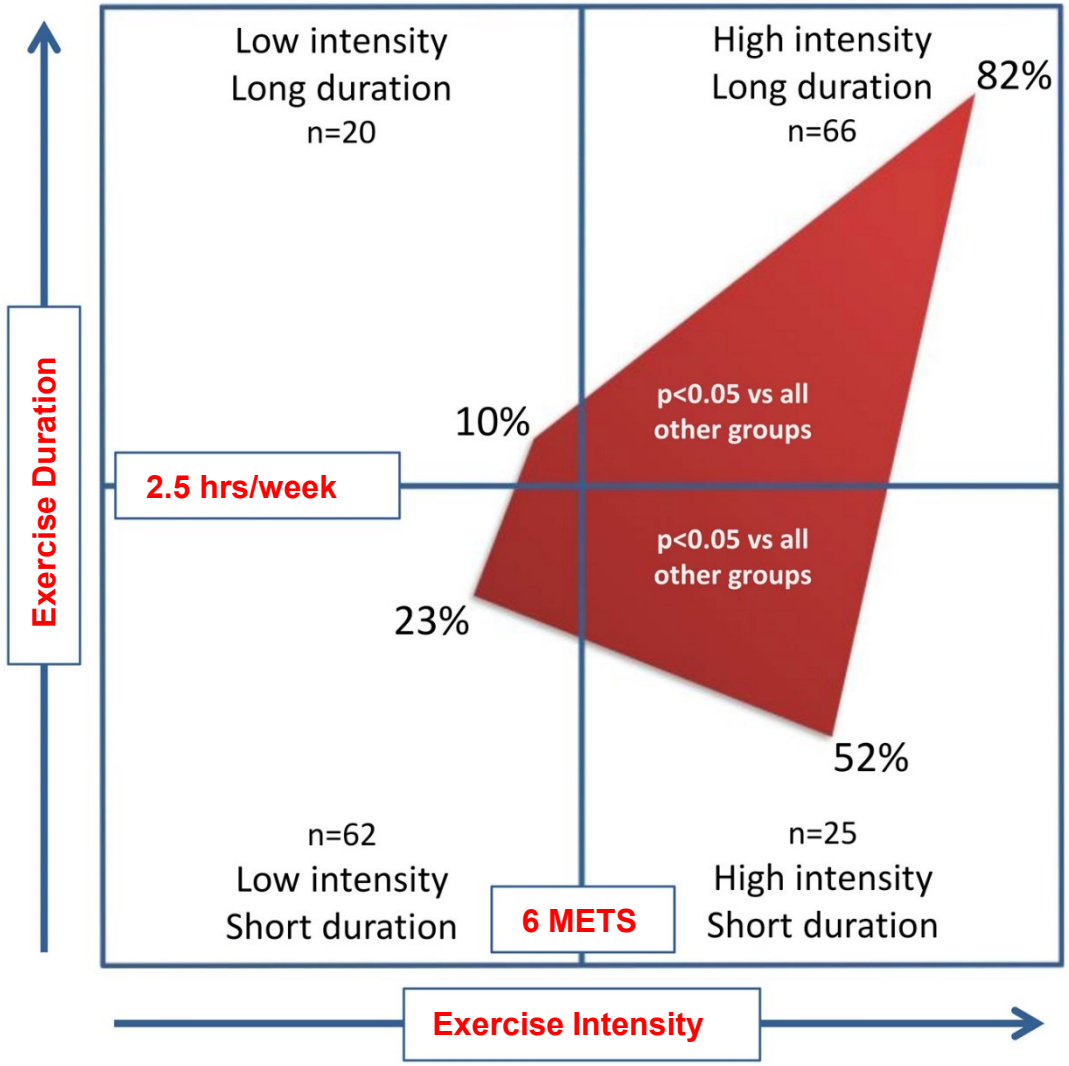



≤ 2.5 hours / week

➔ ***Exercise intensity seems more harmful than exercise duration***

JACC Clin Electrophysiol. 2018 Jun;4(6):744-753


DIAGNOSIS OF ARC

European Heart Journal - Cardiovascular Imaging (2017) **18**, 237–253
doi:10.1093/ehjci/jew229

Comprehensive multi-modality imaging approach in arrhythmogenic cardiomyopathy—an expert consensus document of the European Association of Cardiovascular Imaging

Kristina H. Haugaa[1]*, Cristina Basso[2], Luigi P. Badano[3], Chiara Bucciarelli-Ducci[4], Nuno Cardim[5], Oliver Gaemperli[6], Maurizio Galderisi[7], Gilbert Habib[8], Juhani Knuuti[9], Patrizio Lancellotti[10], William McKenna[11], Danilo Neglia[12], Bogdan A. Popescu[13], Thor Edvardsen[1]

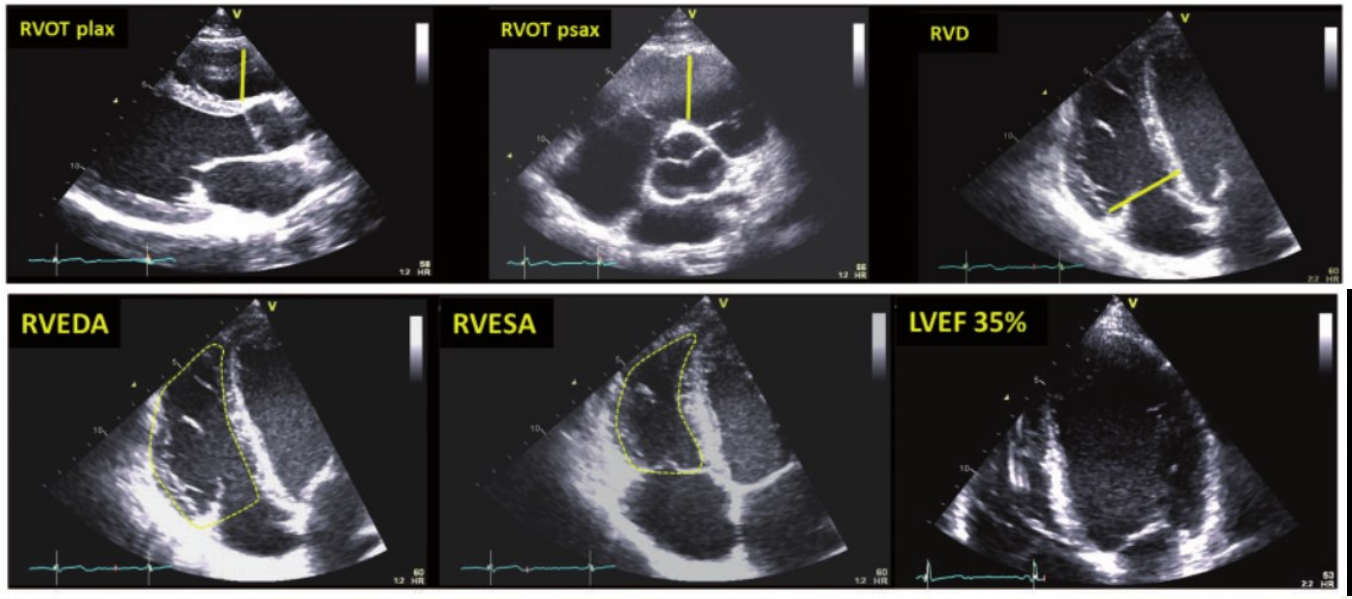

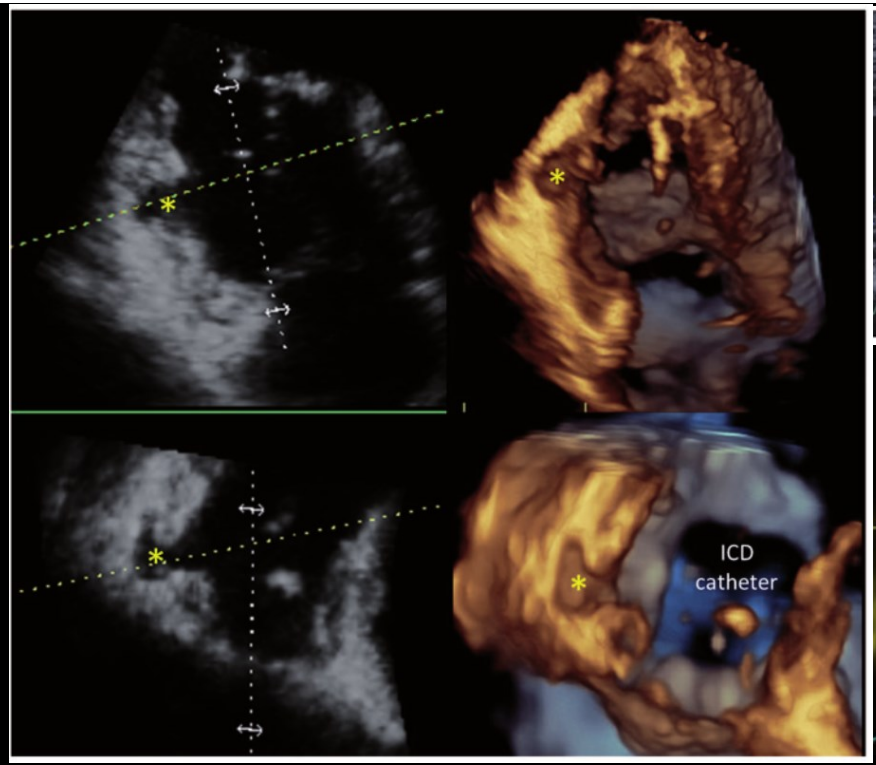

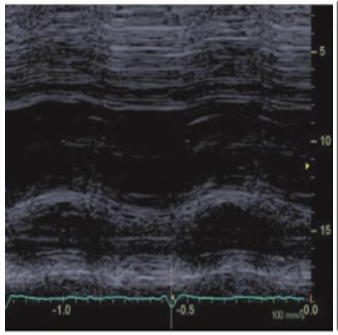

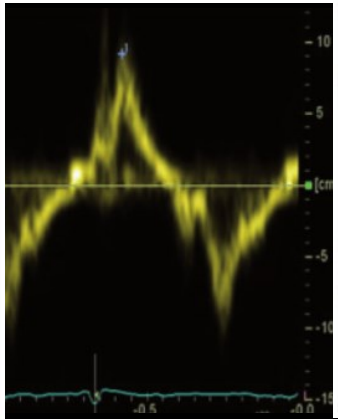

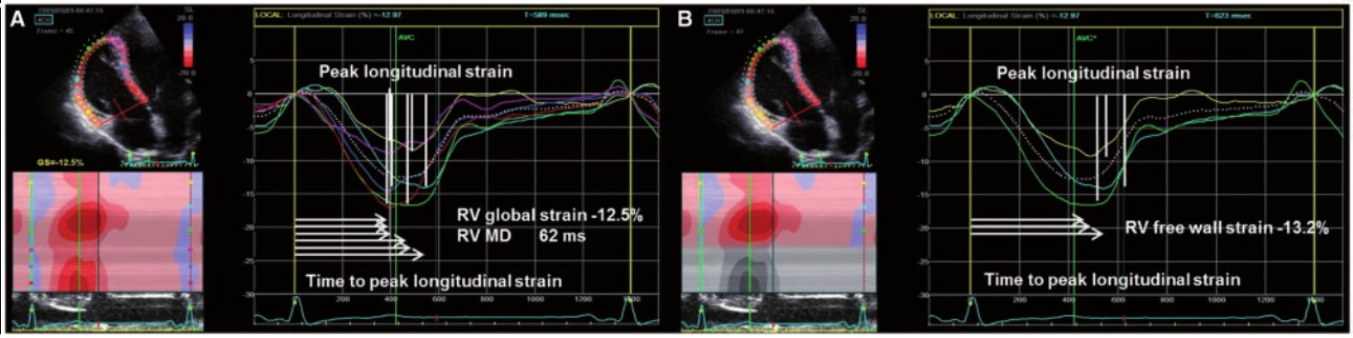

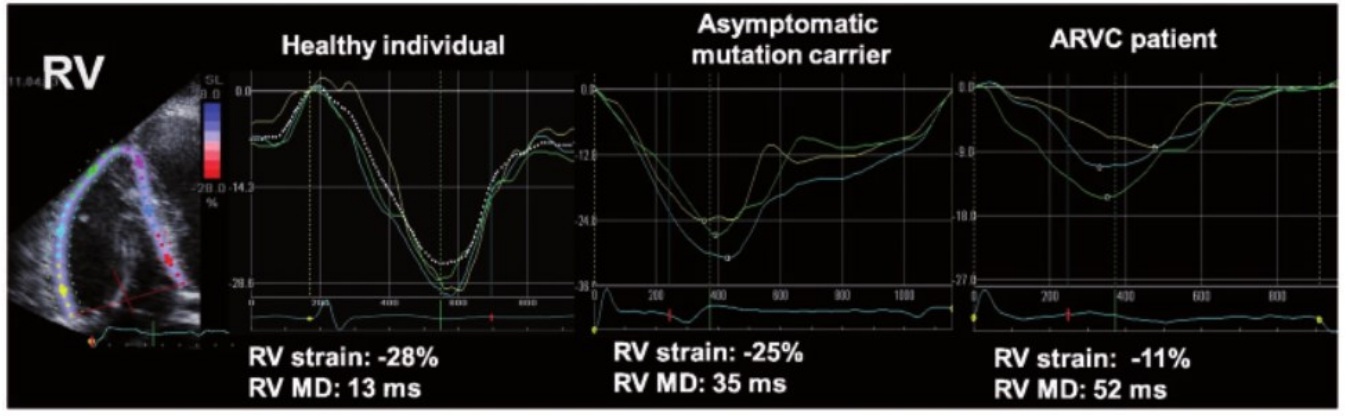

E C H O C A R D I O G R A P H Y

European Heart Journal - Cardiovascular Imaging (2017) **18**, 237–253
doi:10.1093/ehjci/jew229

Comprehensive multi-modality imaging approach in arrhythmogenic cardiomyopathy—an expert consensus document of the European Association of Cardiovascular Imaging

Kristina H. Haugaa[1]*, Cristina Basso[2], Luigi P. Badano[3], Chiara Bucciarelli-Ducci[4], Nuno Cardim[5], Oliver Gaemperli[6], Maurizio Galderisi[7], Gilbert Habib[8], Juhani Knuuti[9], Patrizio Lancellotti[10], William McKenna[11], Danilo Neglia[12], Bogdan A. Popescu[13], Thor Edvardsen[1]

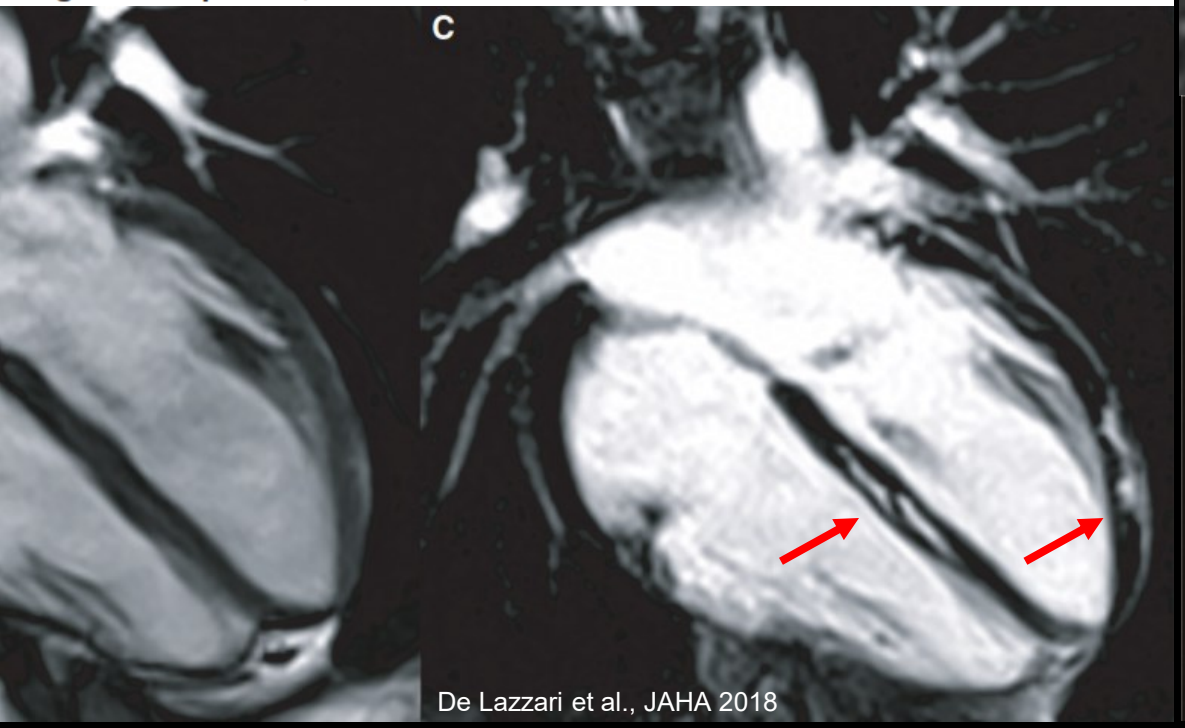

De Lazzari et al., JAHA 2018

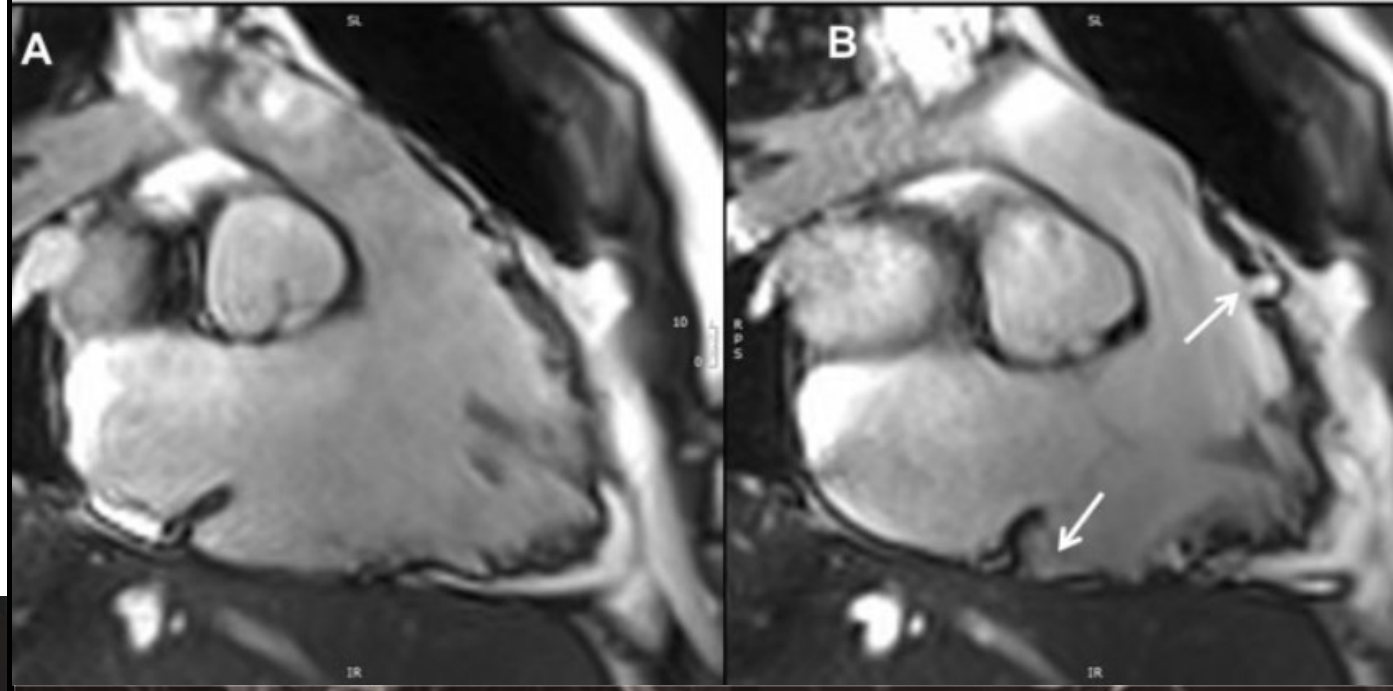

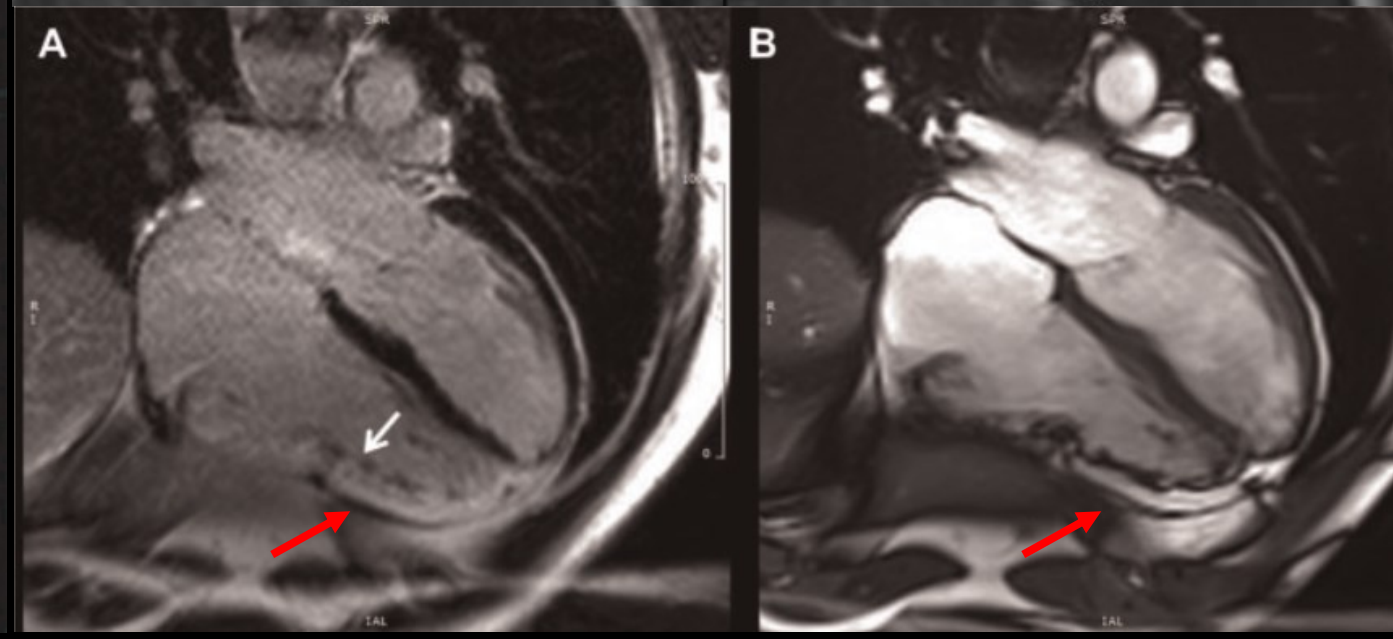

C A R D I A C - M R I

Arrhythmogenic Cardiomyopathy

Prognostic Role of CMR

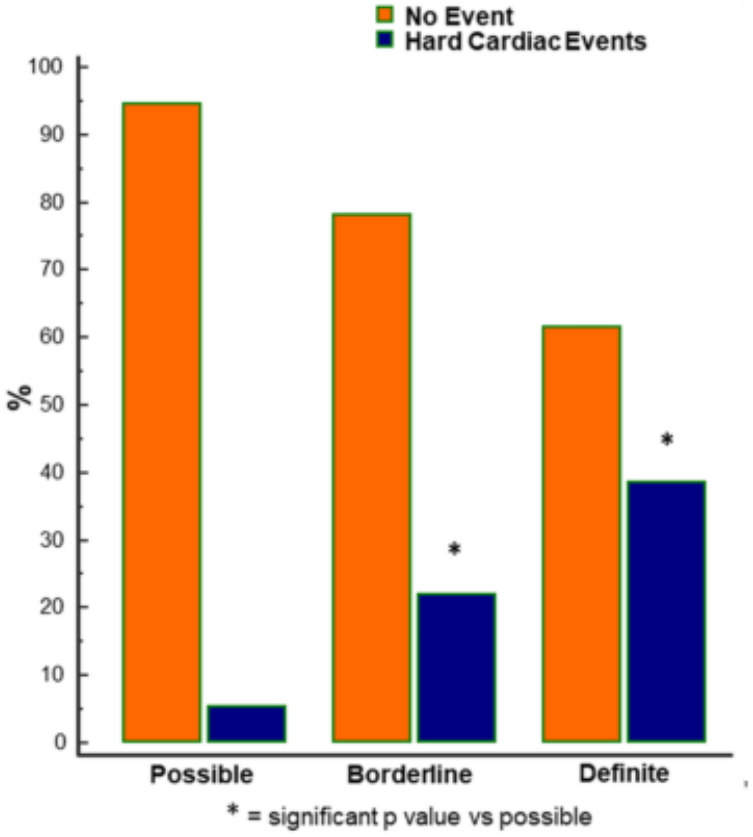

n=175

Aquaro-GD et al., Am J Cardiol 2018

Arrhythmogenic Right Ventricular Cardiomyopathy: Characterization of Left Ventricular Phenotype and Differential Diagnosis With Dilated Cardiomyopathy

Alberto Cipriani, MD; Barbara Bauce, MD, PhD; Manuel De Lazzari, MD, PhD; Ilaria Rigato, MD, PhD; Riccardo Bariani, MD; Samuele Meneghin, MD; Kalliopi Pilichou, MD, PhD; Raffaella Motta, MD, PhD Camillo Aliberti, MD; Gaetano Thiene, MD; William J. McKenna, MD, DSc; Alessandro Zorzi, MD, PhD; Sabino Iliceto, MD; Cristina Basso, MD, PhD; Martina Perazzolo Marra, MD, PhD;* Domenico Corrado, MD, PhD*

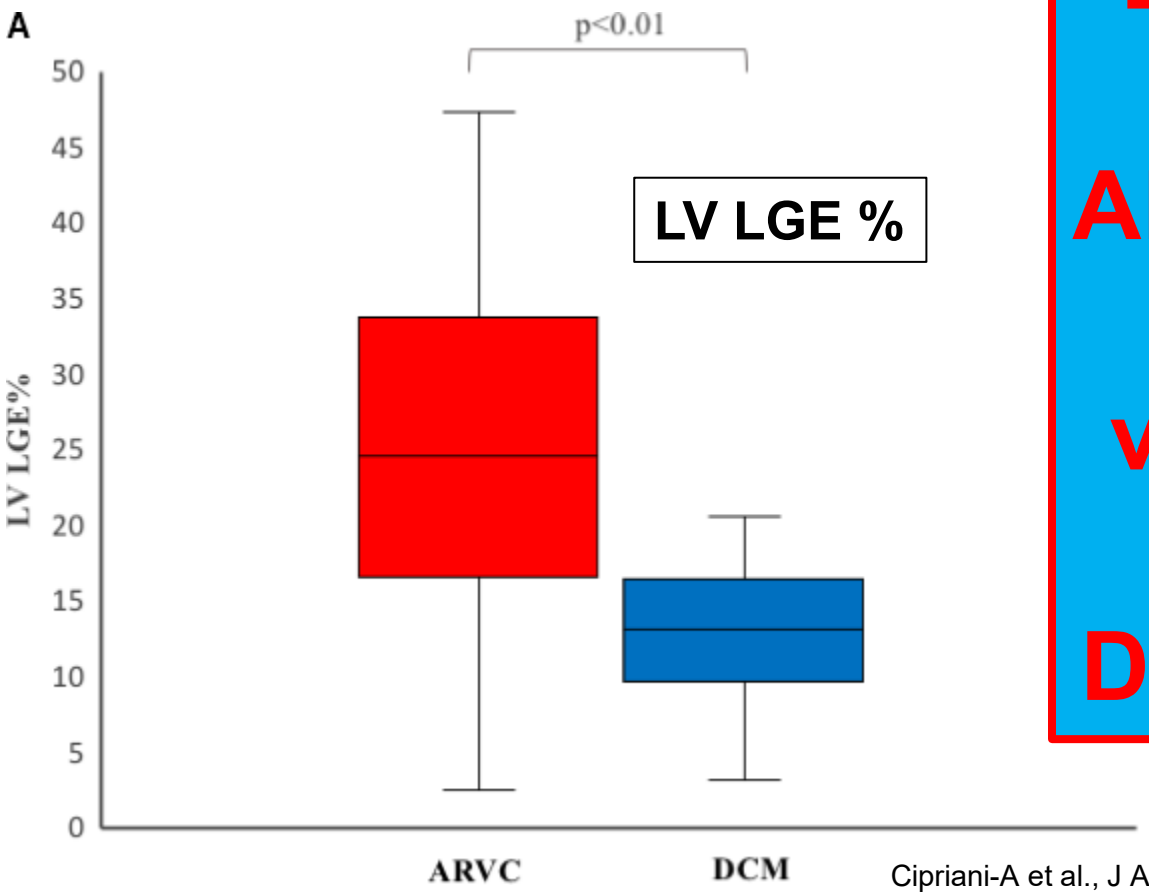

DD ARC vs. DCM

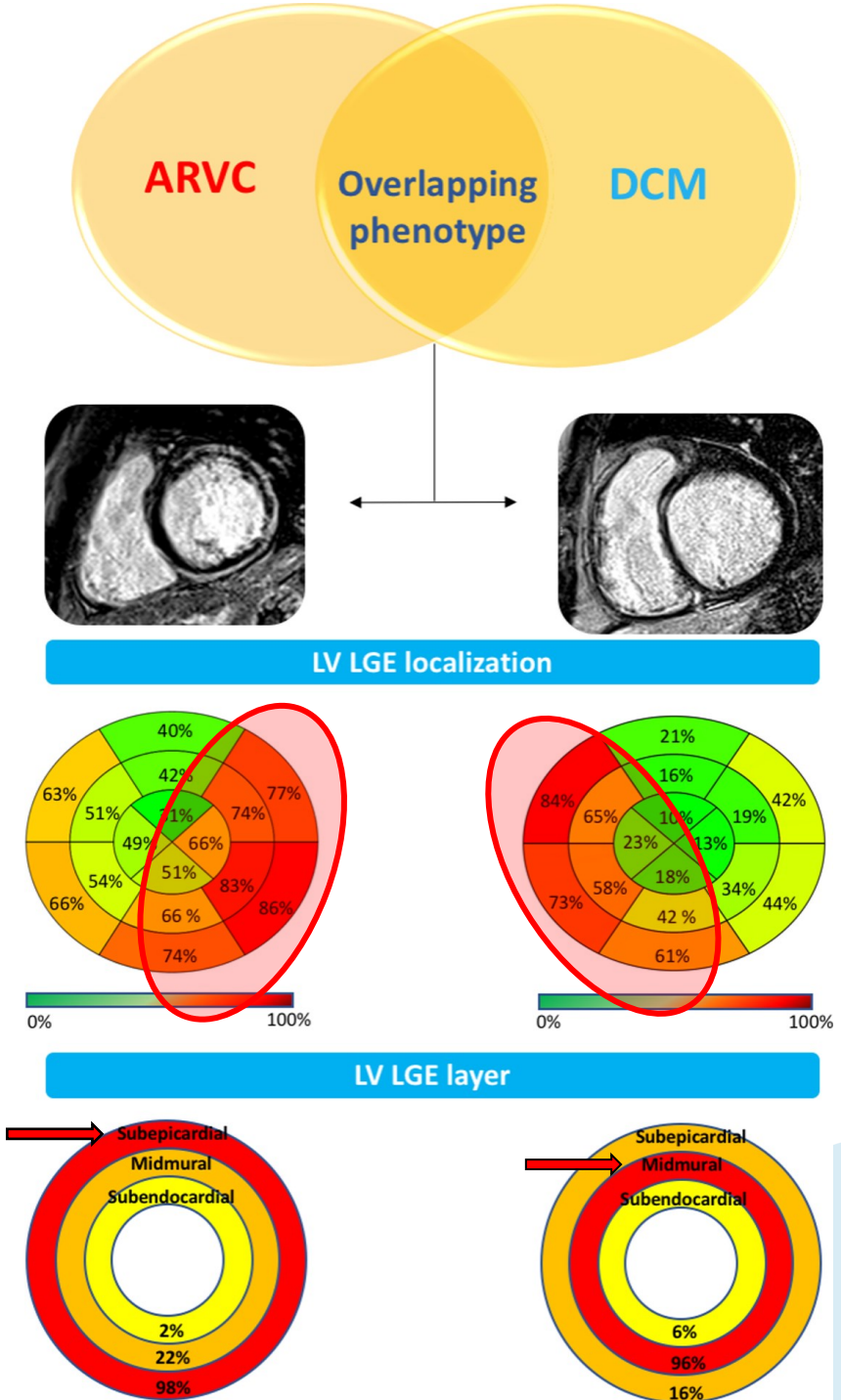

Cipriani-A et al., J Am Heart Assoc 2020

	ARVC-LV Phenotype n=41	DCM-LV Phenotype (LVEF >40%) n=32	*P* Value
Electrocardiographic characteristics			
First degree atrioventricular block	5 (12)	4 (13)	0.969
Complete left bundle branch block	0	11 (34)	<0.001
Sokolow-Lyon Index	1 (2)	7 (22)	0.018
Left axis deviation	7 (17)	10 (31)	0.155
Left anterior fascicular block	5 (12)	6 (19)	0.518
Left atrial enlargement	6 (15)	6 (19)	0.638
Strain pattern	1 (2)	3 (9)	0.313
Low (<0.5 mV) QRS voltages in limb leads	24 (59)	1 (3)	<0.001
TWI in anterolateral leads (V1–V6)	11 (27)	2/23 (9)*	0.043
TWI in lateral leads (V5–V6±V4, I, aVL)	20 (49)	4/23 (17)*	0.001
TWI in inferolateral leads (II, III, aVF+[V5–V6± V4 or I, aVL])	13 (32)	2 (6)	<0.001
CMR findings			
LV EDV, mL/m^2	97 (90–108)	120 (108–136)	<0.001
LV dilatation	19 (46)	32 (100)	<0.001
CMR LV mass, g/m^2	66 (55–73)	79 (63–90)	0.012
LV regional WMA	38 (93)	6 (19)	<0.001
LV global WMA	3 (7)	26 (81)	<0.001
LVEF, %	46 (41–48)	43 (41–45)	0.091
CMR tissue characterization findings			
LV LGE amount, g	17.2 (12.3–22.5)	7.8 (6.4–13.1)	<0.001
LV LGE amount, %	24.6 (16.8–33.3)	10.4 (8.3–17.3)	<0.001
N° segments involved	9 (7–11)	5 (3–7)	<0.001
>6 segments	32 (78)	7 (22)	<0.001
LV LGE morphology			
Stria	40 (98)	27 (84)	0.034
Spot/patchy	6 (15)	6 (19)	0.574
LV LGE layer			
Subendocardial	1 (2)	0	0.956
Midmural	9 (22)	30 (94)	<0.001
Subepicardial	40 (98)	5 (16)	<0.001

LBBB

Low Voltage

TWI inferolat

LV dilat

WMA reg/glob

LV **LGE %**

LV LGE **layer**

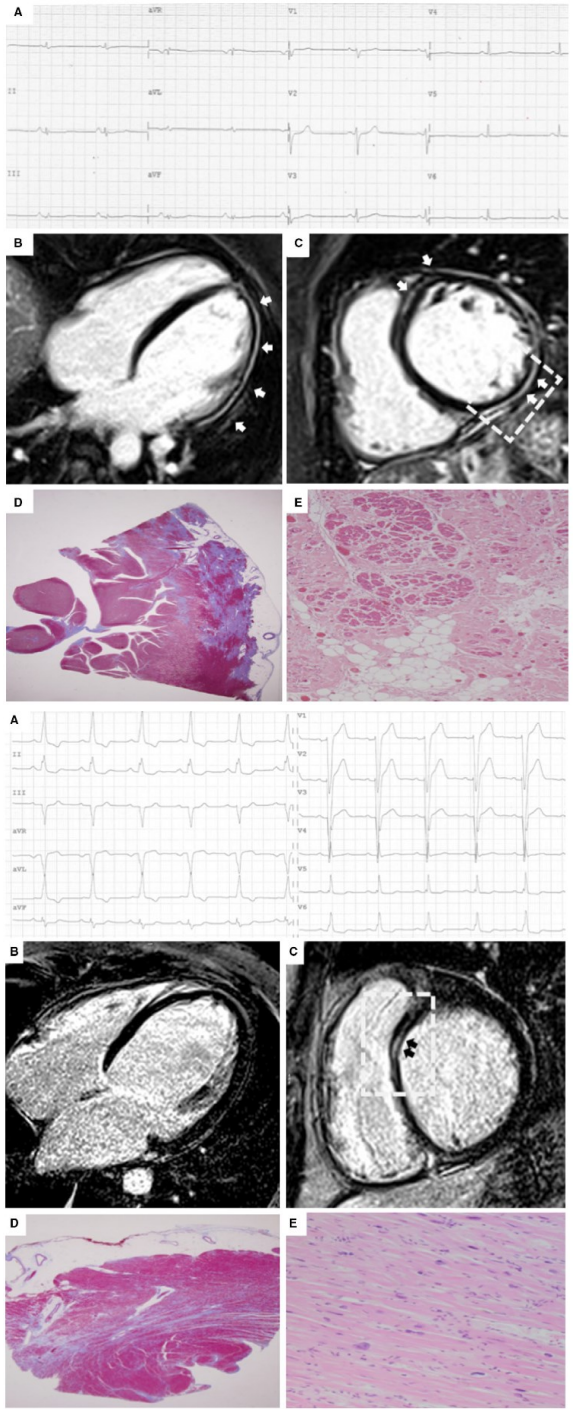

ACM

DCM

AGAPLESION
Unsere Werte verbinden

Cipriani-A et al., J Am Heart Assoc 2020

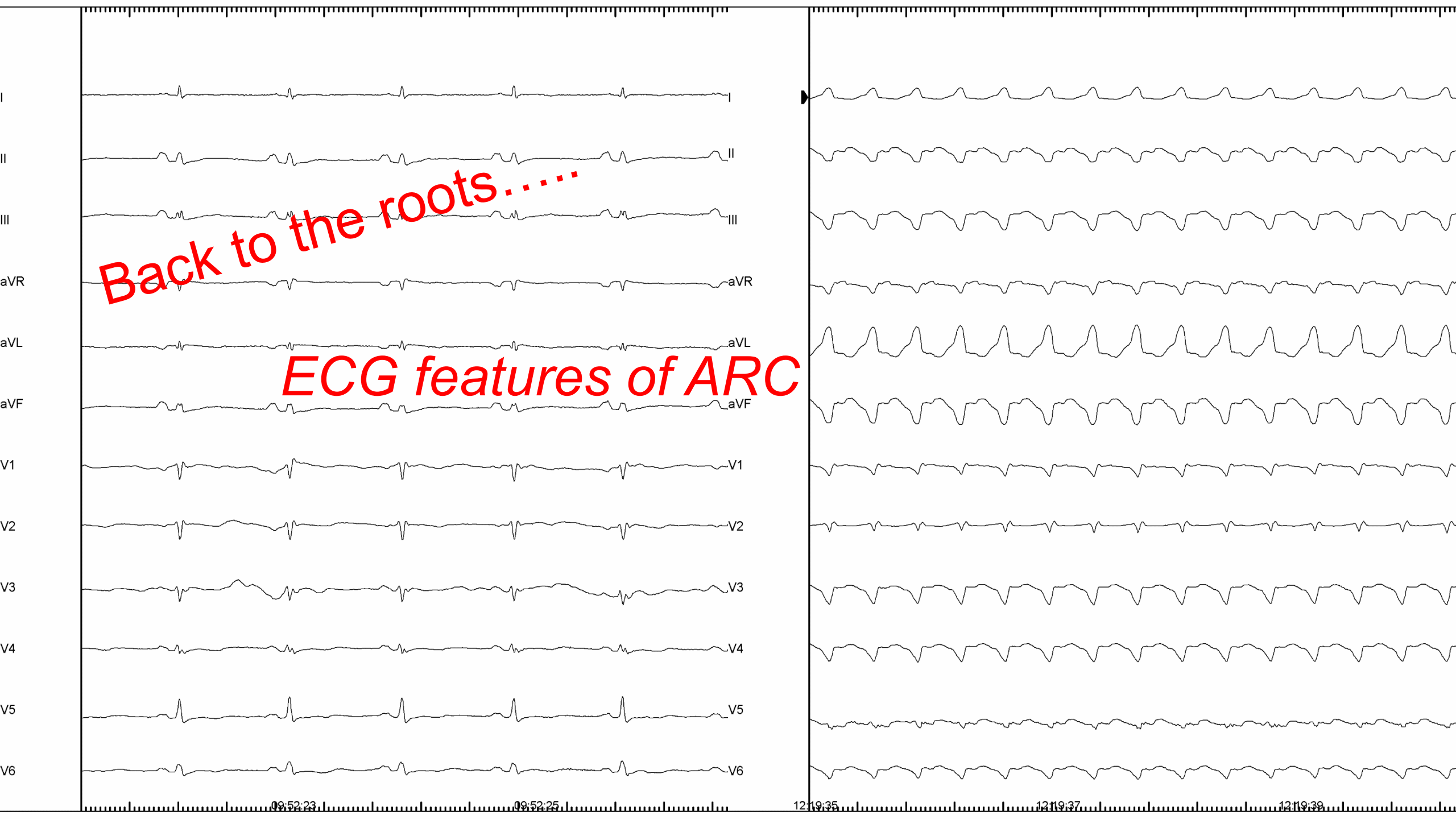
Back to the roots.....
ECG features of ARC
I
II
III
aVR
aVL
aVF
V1
V2
V3
V4
V5
V6
09:52:23
09:52:25
12:19:35
12:19:37
12:19:39

American Heart Association | American Stroke Association

AGAPLESION
Unsere Werte verbinden

ORIGINAL RESEARCH

Relationship Between Electrocardiographic Findings and Cardiac Magnetic Resonance Phenotypes in Arrhythmogenic Cardiomyopathy

Manuel De Lazzari, MD, PhD; Alessandro Zorzi, MD, PhD; Alberto Cipriani, MD; Angela Susana, MD; Giulio Mastella, MD; Alessandro Rizzo, MD; Ilaria Rigato, MD, PhD; Barbara Bauce, MD, PhD; Benedetta Giorgi, MD; Carmelo Lacognata, MD; Sabino Iliceto, MD; Domenico Corrado, MD, PhD; Martina Perazzolo Marra, MD, PhD

Background—The new designation of arrhythmogenic cardiomyopathy defines a broader spectrum of disease phenotypes, which include right dominant, biventricular, and left dominant variants. We evaluated the relationship between electrocardiographic findings and contrast-enhanced cardiac magnetic resonance phenotypes in arrhythmogenic cardiomyopathy.

Methods and Results—We studied a consecutive cohort of patients with a definite diagnosis of arrhythmogenic cardiomyopathy, according to 2010 International Task Force criteria, who underwent electrocardiography and contrast-enhanced cardiac magnetic resonance. Both depolarization and repolarization electrocardiographic abnormalities were correlated with the severity of dilatation/dysfunction, either global or regional, of both ventricles and the presence and regional distribution of late gadolinium enhancement. The study population included 79 patients (60% men). There was a statistically significant relationship between the presence and extent of T-wave inversion across a 12-lead ECG and increasing values of median right ventricular (RV) end-diastolic volume ($P<0.001$) and decreasing values of RV ejection fraction ($P<0.001$). The extent of T-wave inversion to lateral leads predicted a more severe RV dilatation rather than a left ventricular involvement because of the leftward displacement of the dilated RV, as evidenced by contrast-enhanced cardiac magnetic resonance. A terminal activation delay of >55 ms in the right precordial leads (V1-V3) was associated with higher RV volume ($P=0.014$) and lower RV ejection fraction ($P=0.053$). Low QRS voltages in limb leads predicted the presence ($P=0.004$) and amount ($P<0.001$) of left ventricular late gadolinium enhancement.

Conclusions—The study results indicated that electrocardiographic abnormalities predict the arrhythmogenic cardiomyopathy phenotype in terms of severity of RV disease and left ventricular involvement, which are among the most important determinants of the disease outcome. (***J Am Heart Assoc.* 2018;7:e009855. DOI: 10.1161/JAHA.118.009855.**)

Key Words: cardiac magnetic resonance imaging • cardiomyopathy • electrocardiography • late gadolinium enhancement

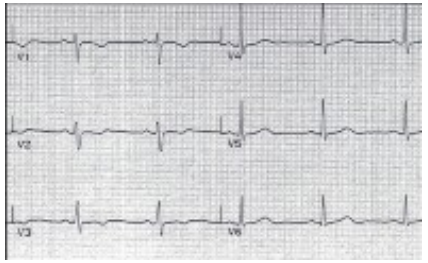

ACM
n=79

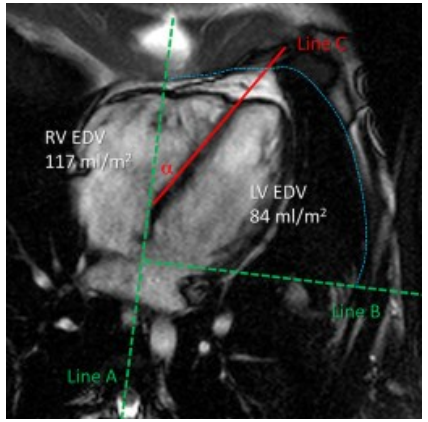

De Lazzari et al., JAHA 2018

Arrhythmogenic Cardiomyopathy

ECG Features

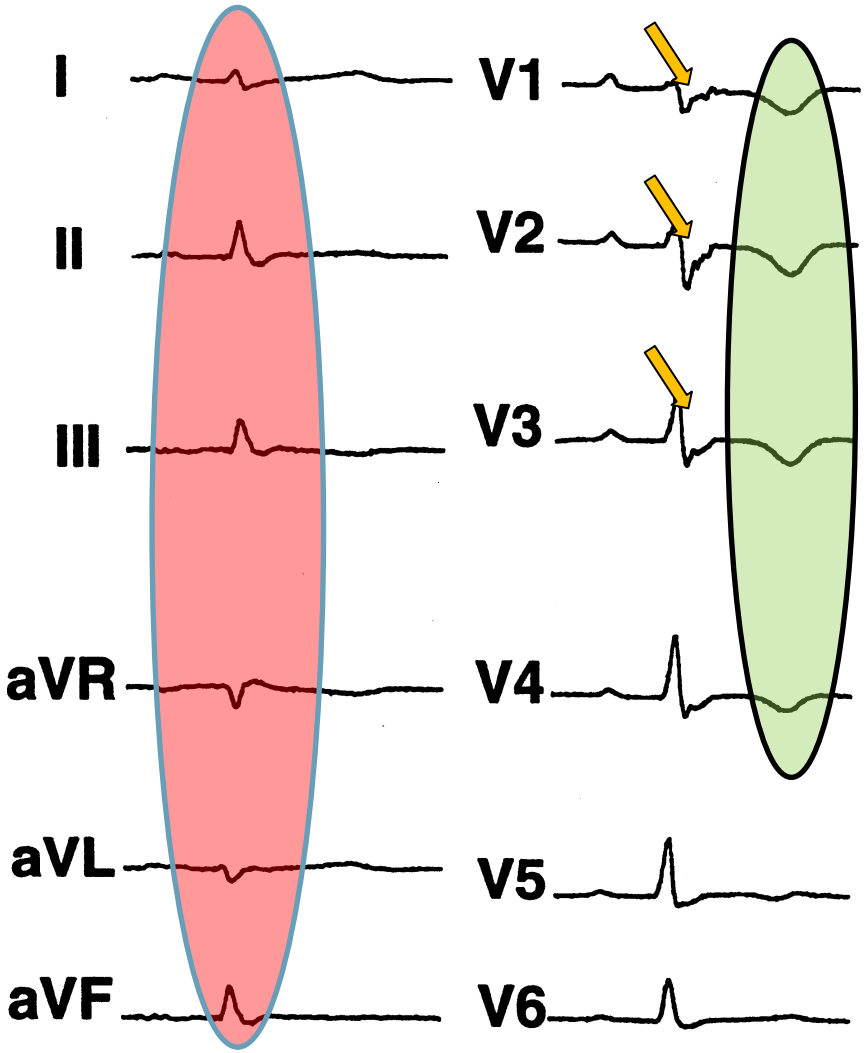

Wichter et al. Z Kardiol. 1991

Extent of negative T-waves in right precordial leads
➔ correlates with the ***severity of RV dilatation & dysfunction***
➔ does not predict LV involvement!

(In-)complete RBBB, Ɛ-waves, delayed S-wave upstroke, terminal activation delay (TAD, peak S - J point) >55ms
➔ reflect areas of slow conduction, fragmentation of electrical activation, ***proarrhythmogenic reentry circuits***

Low-voltage (≤0,5mV) in limb leads
➔ ***predicts LV involvement*** (Spec 100%, Sens 30%)

De Lazzari et al., JAHA 2018

AGAPLESION
Unsere Werte verbinden

Therapy.

https://www.therapylv.com/

Risikostratifizierung bei ARC

Geschätztes jährliches Risiko eines tödlichen arrhythmischen Ereignisses

Major Arrhythmic Events

Cardiac arrest due to ventricular fibrillation
Sustained ventricular tachycardia

High Risk >10%/yr

Major Risk Factors

Unexplained syncope
Nonsustained ventricular tachycardia
Severe right or left ventricular dysfunction

Minor Risk Factors

Proband status, male sex
Frequent PVBs (≥1000/24 hr)
Inducibility on electrophysiological study
Extent of negative T waves
Amount of right ventricular fibrofatty scarring
Multiple desmosomal gene mutations

Intermediate Risk 1–10%/yr

No Events or Risk Factors

Healthy gene carriers
Patients with definite ARVC

Low Risk <1%/yr

Corrado-D et al., NEJM 2017

Arrhythmogenic Cardiomyopathy

HRS Recommendations for ICD Implantation

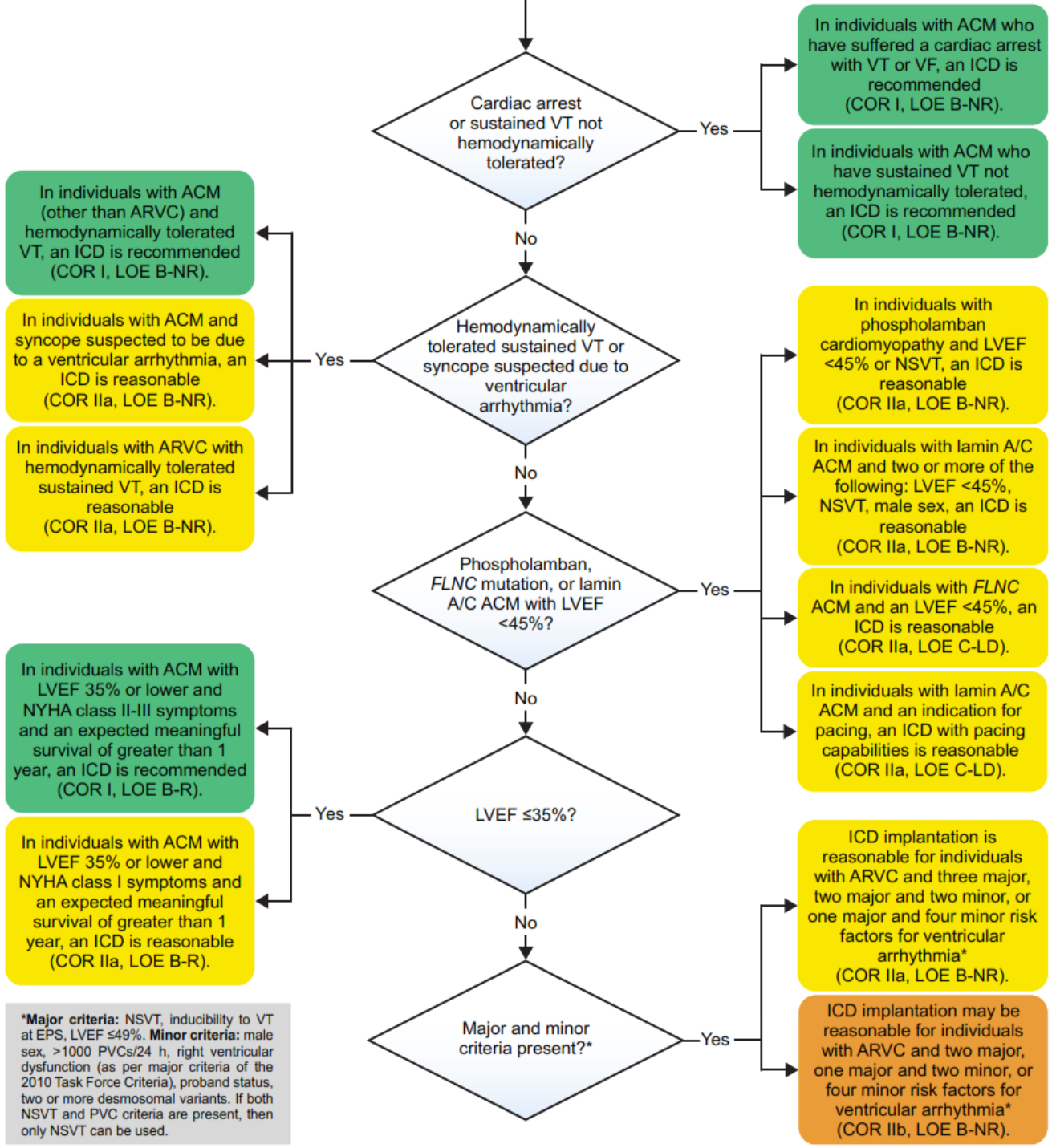

Class I Indication if …

- survived sudden cardiac death
- documented sustained VT
- LV-EF <35%, NYHA ≥ II

Class II Indication if …

- specific genetic variants (Phospholamban, Lamin A/C, FLNC…)
- … & NSVT, reduced LV-EF <45%
- LV-EF <35% & NYHA I

Towbin-JA et al., HRS Consensus ARC, Heart Rhythm 2019

Prediction of Ventricular Arrhythmias in ARC

Cadrin-Tourigny-J et al., Eur Heart J 2019

Prediction of sustained ventricular arrhythmia in ARVC

5-year event-free survival (n = 528)
Overall

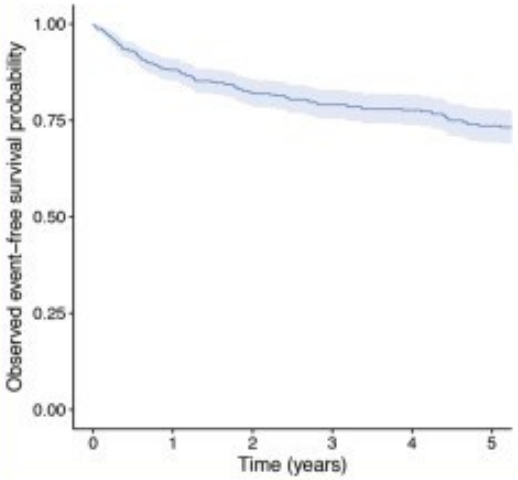

Model for 5-year risk prediction

Sex	x	0.49
Age	x	-0.022
Recent syncope	x	0.66
Non-sustained VT	x	0.81
Ln(24h PVC count)	x	0.17
Leads with T-wave inv.	x	0.11
RVEF	x	-0.025

$$1 - 0.802^{\exp(\quad)} = \text{5 year risk}$$

5-year event-free survival (n = 528)
Per predicted risk group

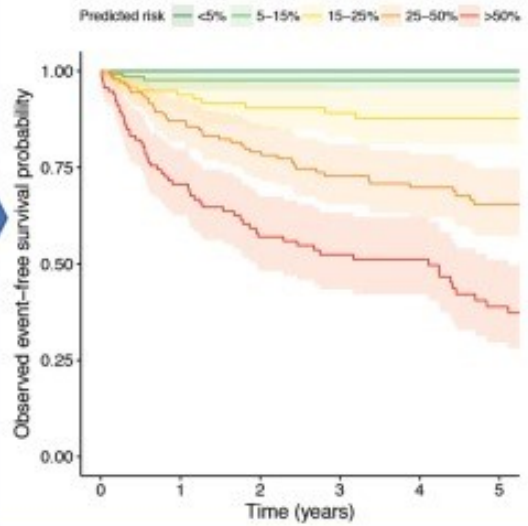

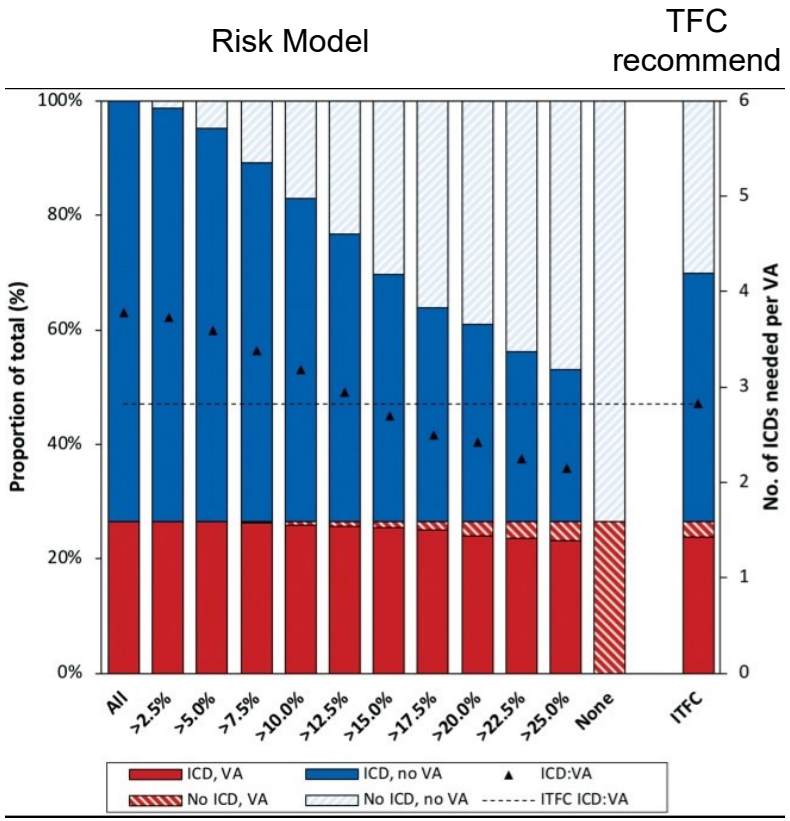

Eur Heart J 2019 Jun 14;40(23):1850-1858

Prediction of Ventricular Arrhythmias in ARC

Lie-Ø et al., JACC CV Imag 2018

LV mechanical dispersion

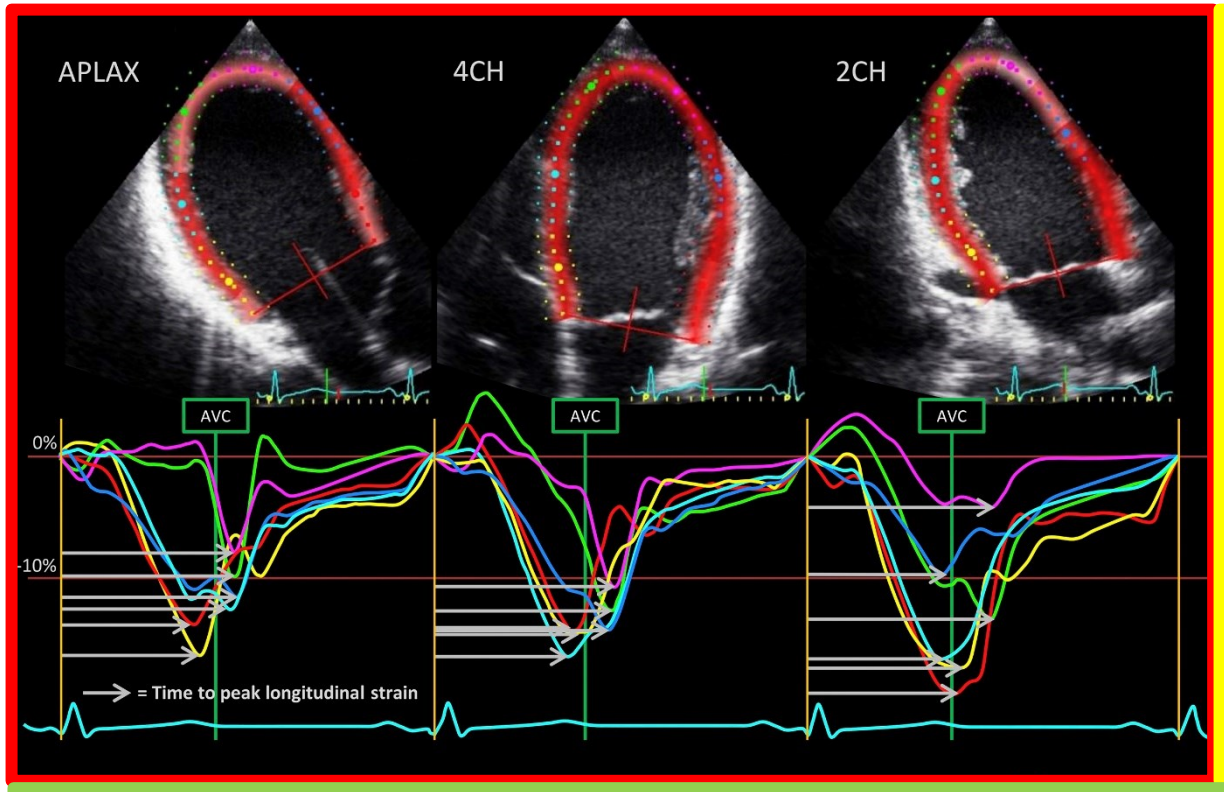

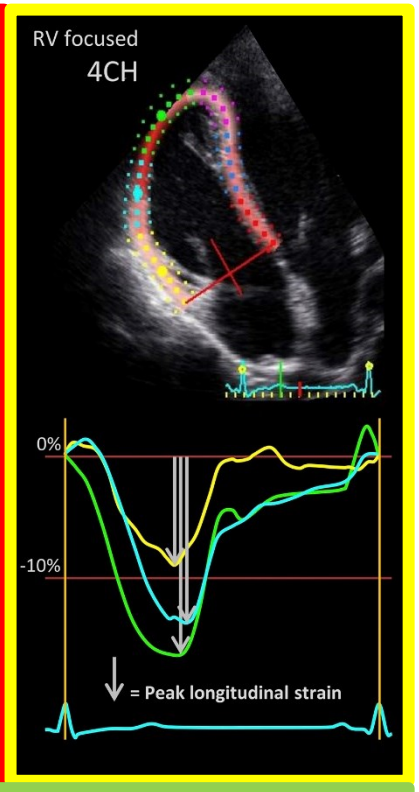

RV free wall strain

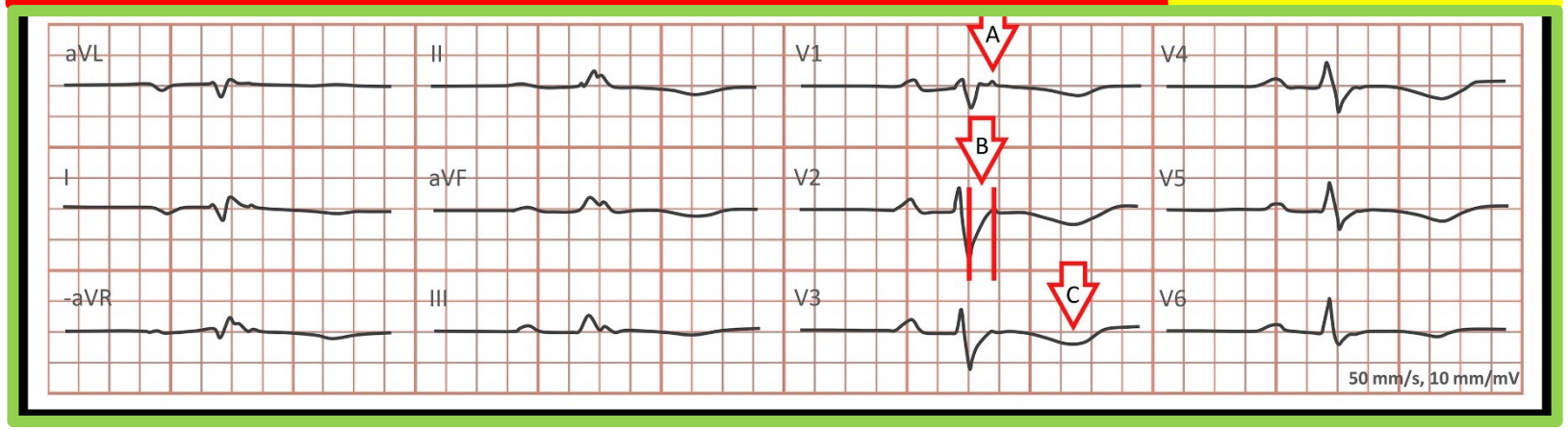

ECG features

A: epsilon potentials

B: terminal activ. dur >55ms

C: extent of T-wave inversion

JACC Cardiovasc Imaging. 2018 11(10):1377-1386

Prediction of Ventricular Arrhythmias in ARC

Lie-Ø et al., JACC CV Imag 2018

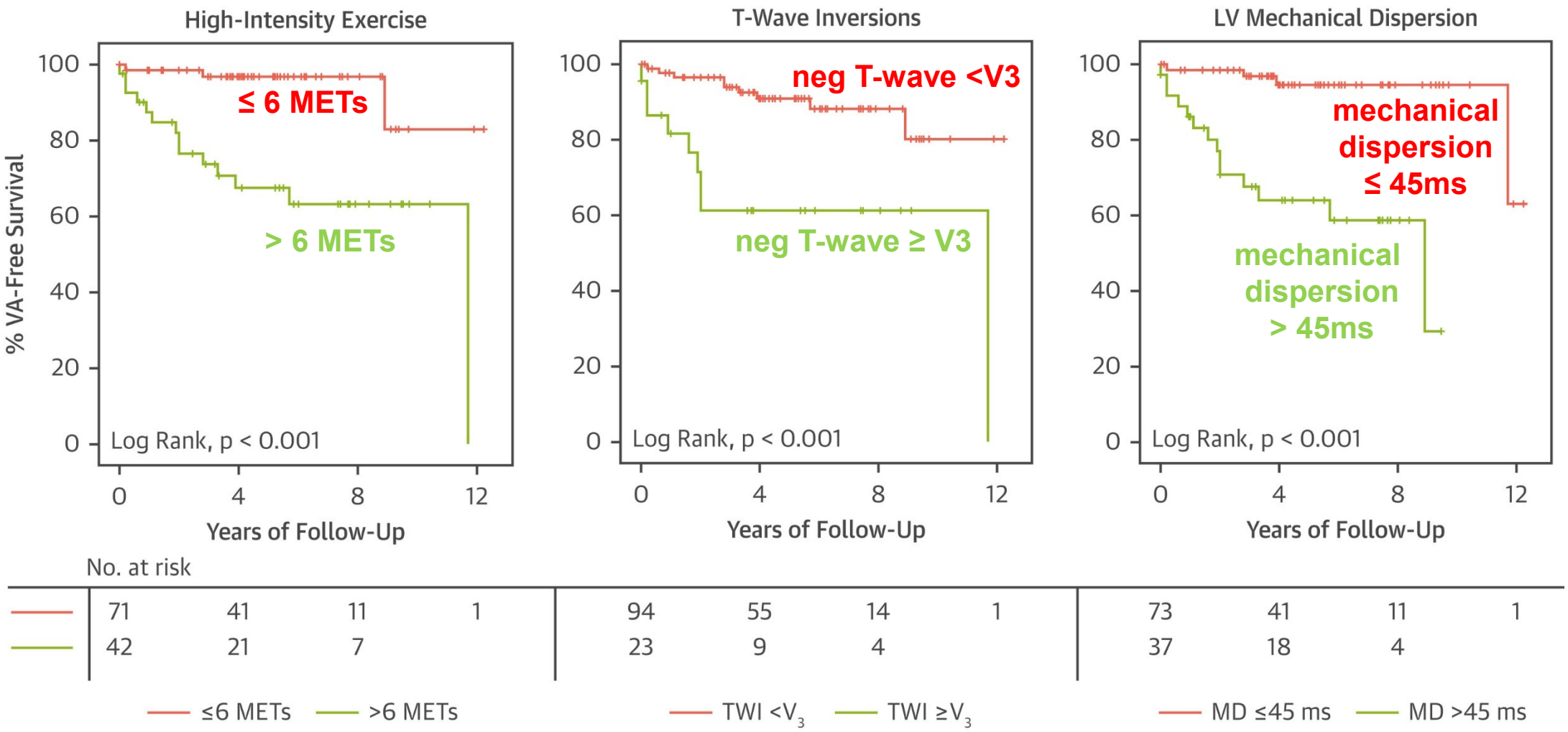

JACC Cardiovasc Imaging. 2018; 11(10):1377-1386

Prediction of Ventricular Arrhythmias in ARC

Lie-Ø et al., JACC CV Imag 2018

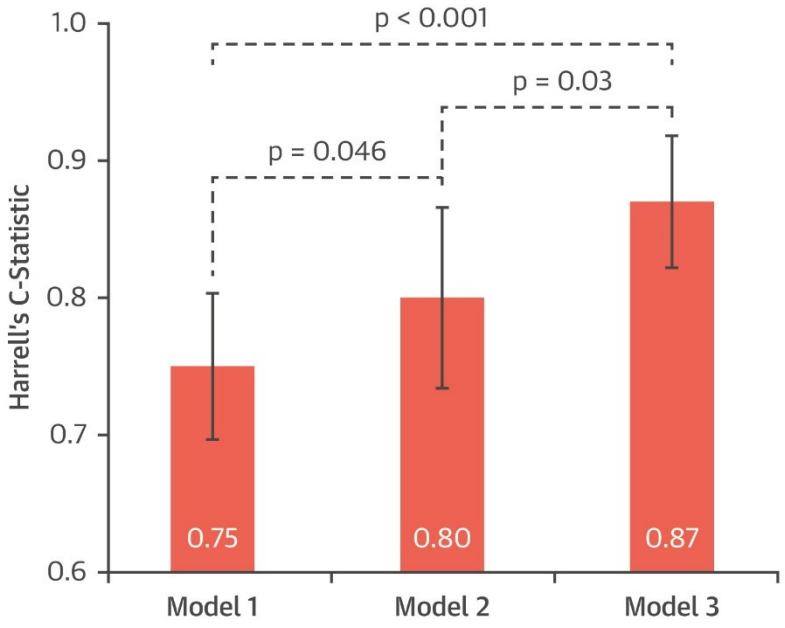

	HR (95% CI)	HR (95% CI)	HR (95% CI)
High int exercise	8.1 (2.3-28.4) p = 0.001	8.1 (2.3-28.8) p = 0.001	4.7 (1.2-17.5) p = 0.02
T-wave inversion		3.9 (1.4-11.1) p = 0.01	4.7 (1.6-13.9) p = 0.005
LV mech dispersion			1.4 (1.2-1.6) p < 0.001
NRI		0.65 (p = 0.01)	0.97 (p < 0.001)
IDI		0.13 (p = 0.008)	0.19 (p = 0.009)
AIC	119.8	115.9	105.0

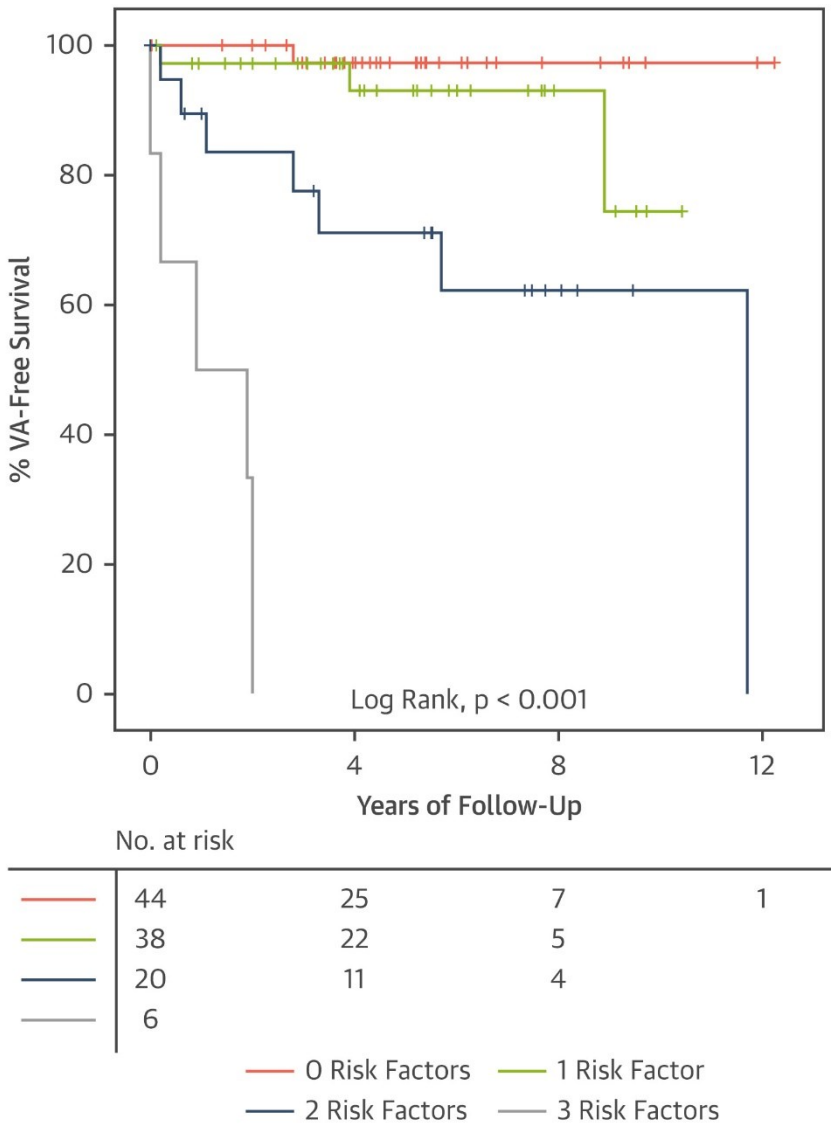

JACC Cardiovasc Imaging. 2018; 11(10):1377-1386

JCI insight

RESEARCH ARTICLE

Stabilization of desmoglein-2 binding rescues arrhythmia in arrhythmogenic cardiomyopathy

Camilla Schinner,[1,2] Bernd Markus Erber,[1] Sunil Yeruva,[1] Angela Schlipp,[1] Vera Rötzer,[1] Ellen Kempf,[1] Sebastian Kant,[3] Rudolf E. Leube,[3] Thomas D. Mueller,[4] and Jens Waschke[1]

[1]Faculty of Medicine, Ludwig-Maximilians-Universität (LMU) Munich, Munich, Germany. [2]Department of Biomedicine, University of Basel, Basel, Switzerland. [3]Institute of Molecular and Cellular Anatomy, RWTH Aachen University, Aachen, Germany. [4]Department of Molecular Plant Physiology and Biophysics, Julius-von-Sachs Institute for Biosciences, Julius-Maximilians-Universität, Würzburg, Germany.

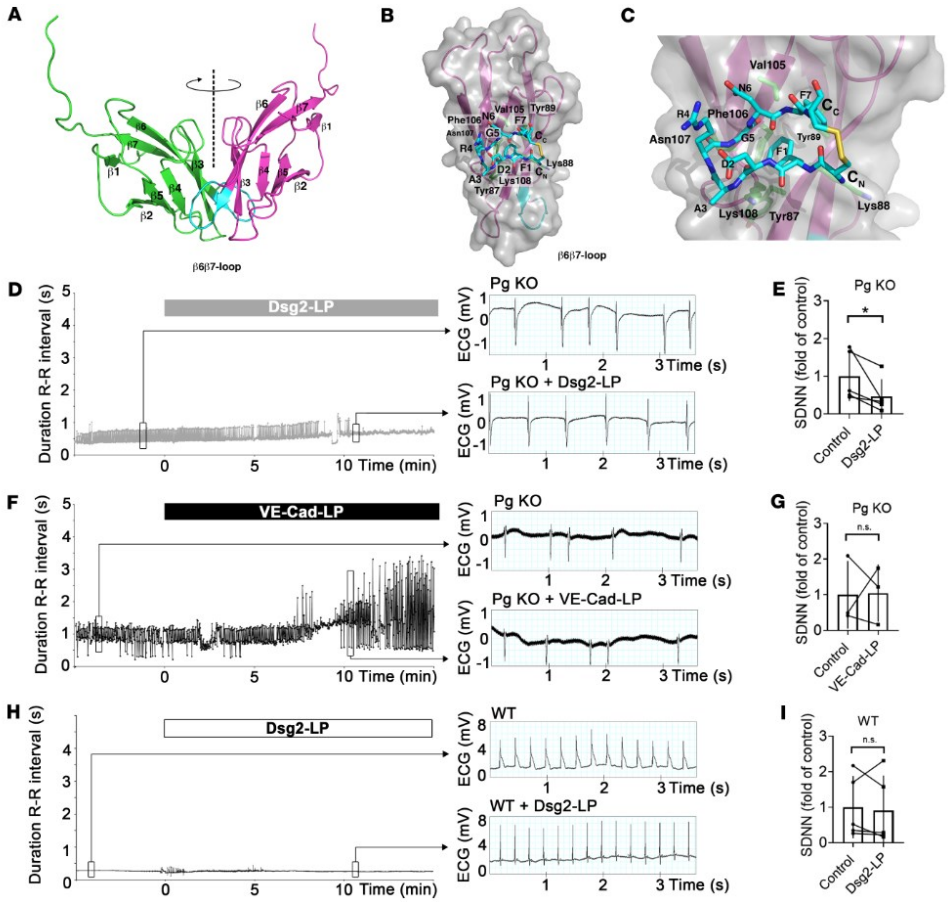

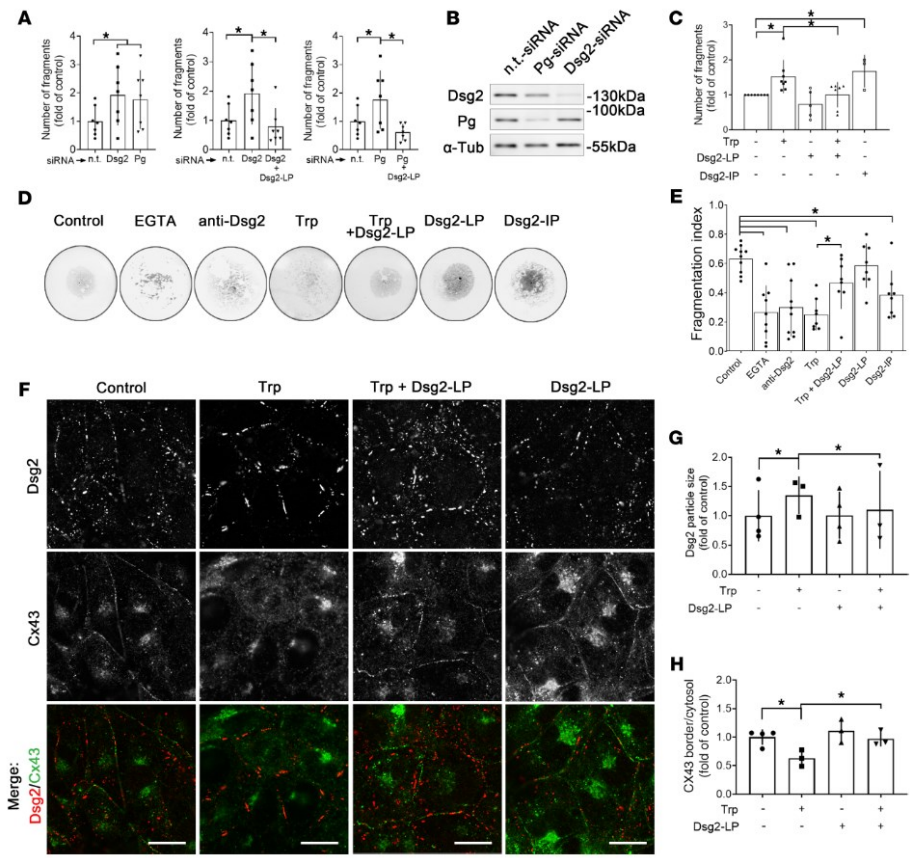

….stabilization of Dsg2 binding by a linking peptide (Dsg2-LP) is efficient to rescue arrhythmia in an AC mouse model ….

…stabilization of Dsg2 binding by Dsg2-LP can serve as a novel approach to treat arrhythmia in patients with AC.

Schinner-C et al., JCI Insight 2020 (epub)

AGAPLESION
Unsere Werte verbinden

Arrhythmogenic Cardiomyopathy

Therapeutic Concepts

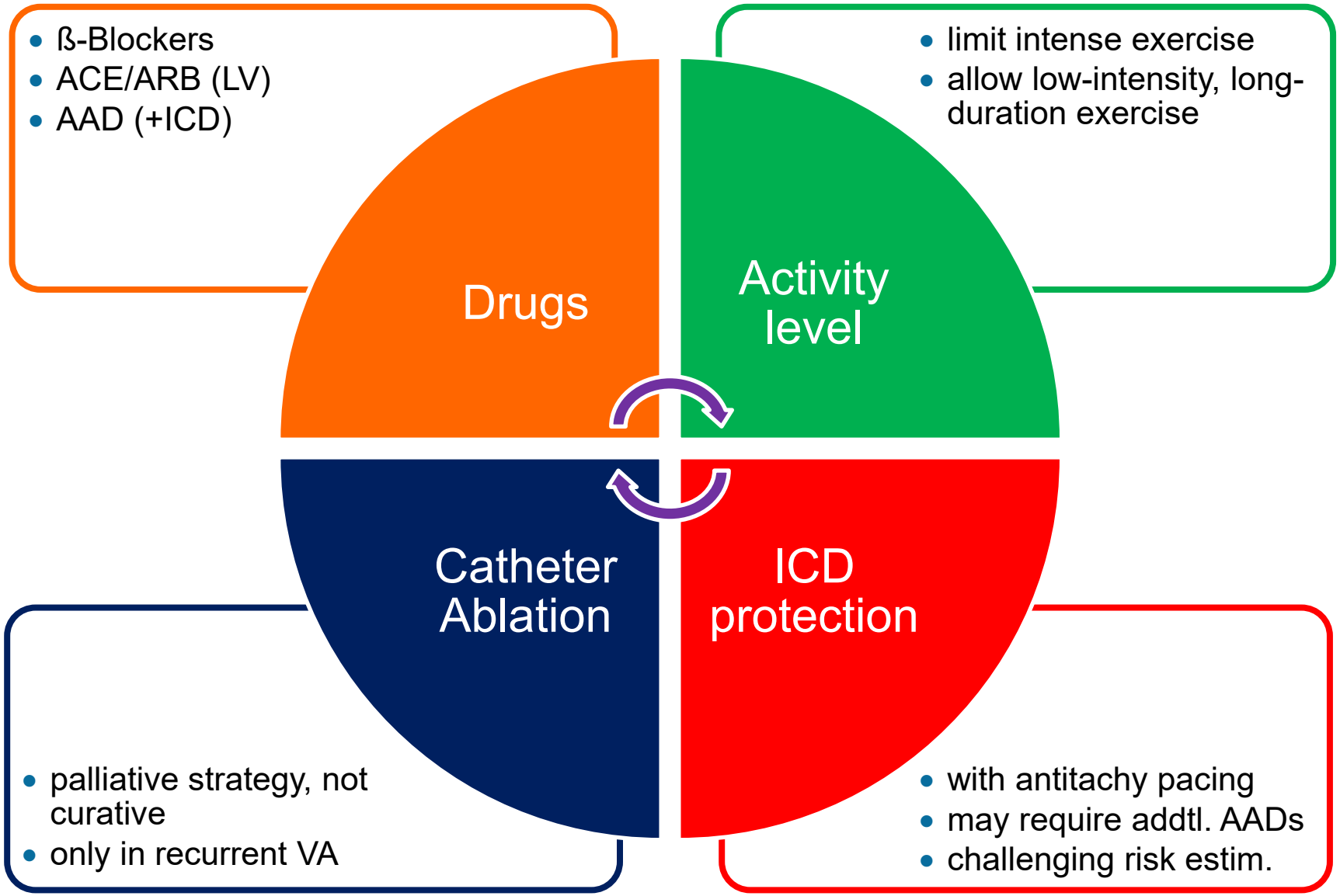

Diagnosis of ACM
Flow-Chart

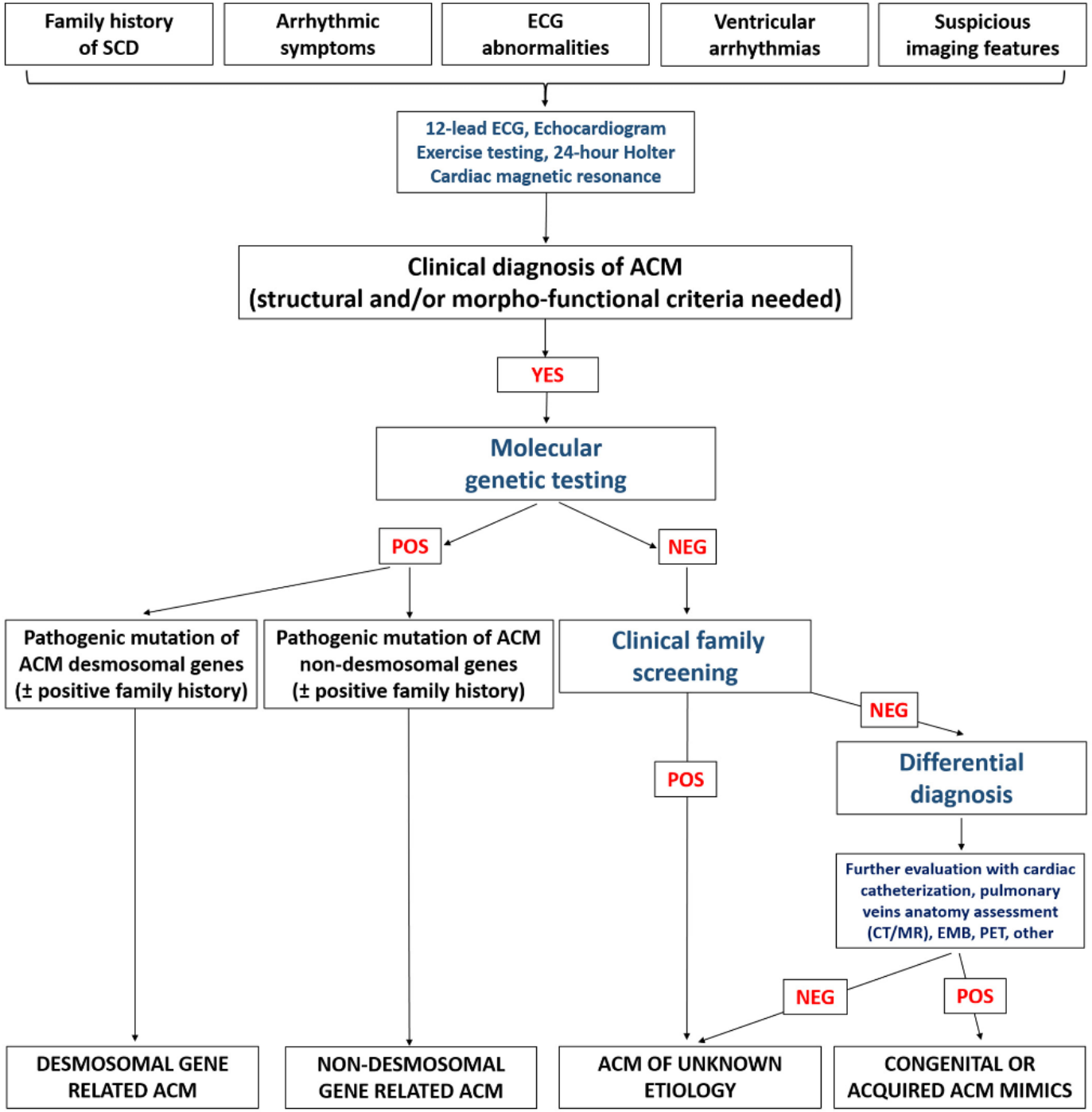

Corrado-D et al., Int J Cardiol 2020 (epub)

Foto: dpa/Stephanie Lecocq

Ablation bei Arrhythmogener Cardiomyopathie & Rezidivierenden VT‘s

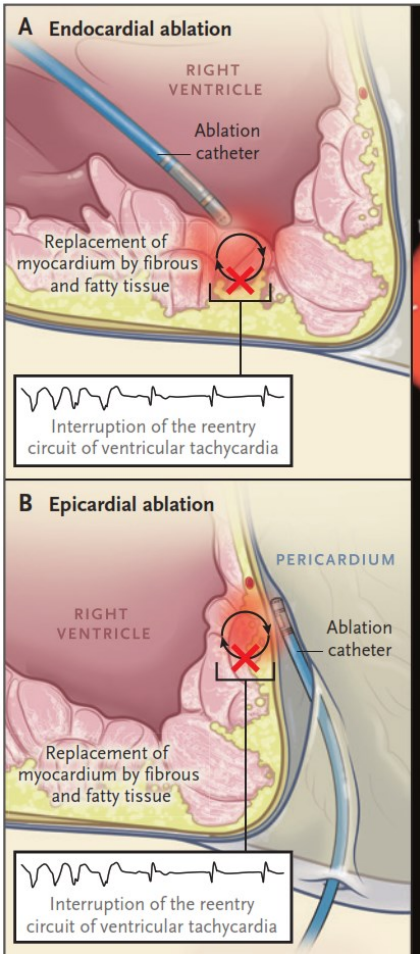

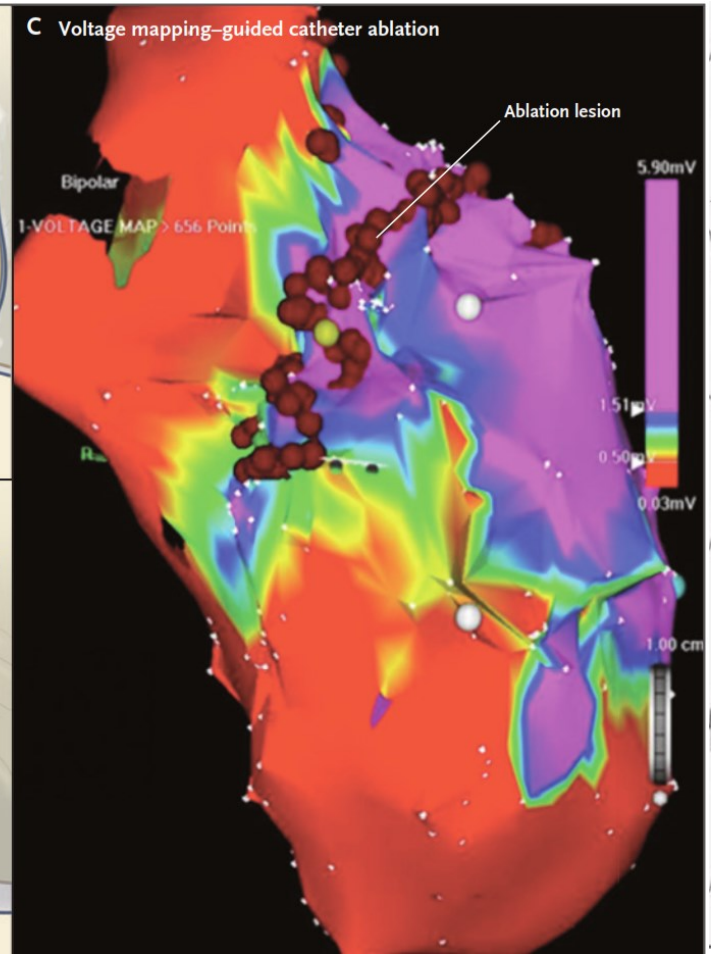

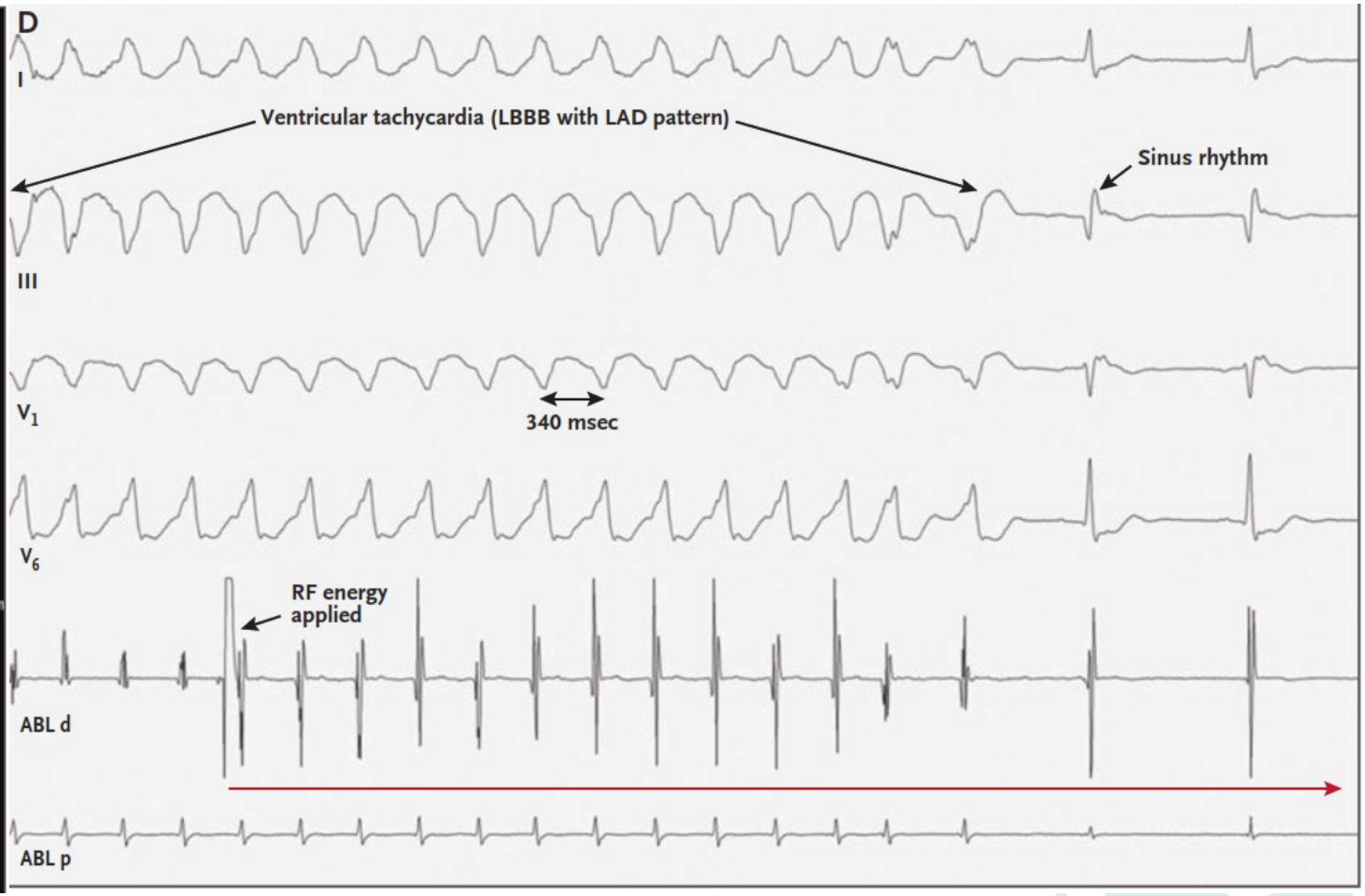

Corrado-D et al., NEJM 2017

Arrhythmogenic Cardiomyopathy

ECG Features

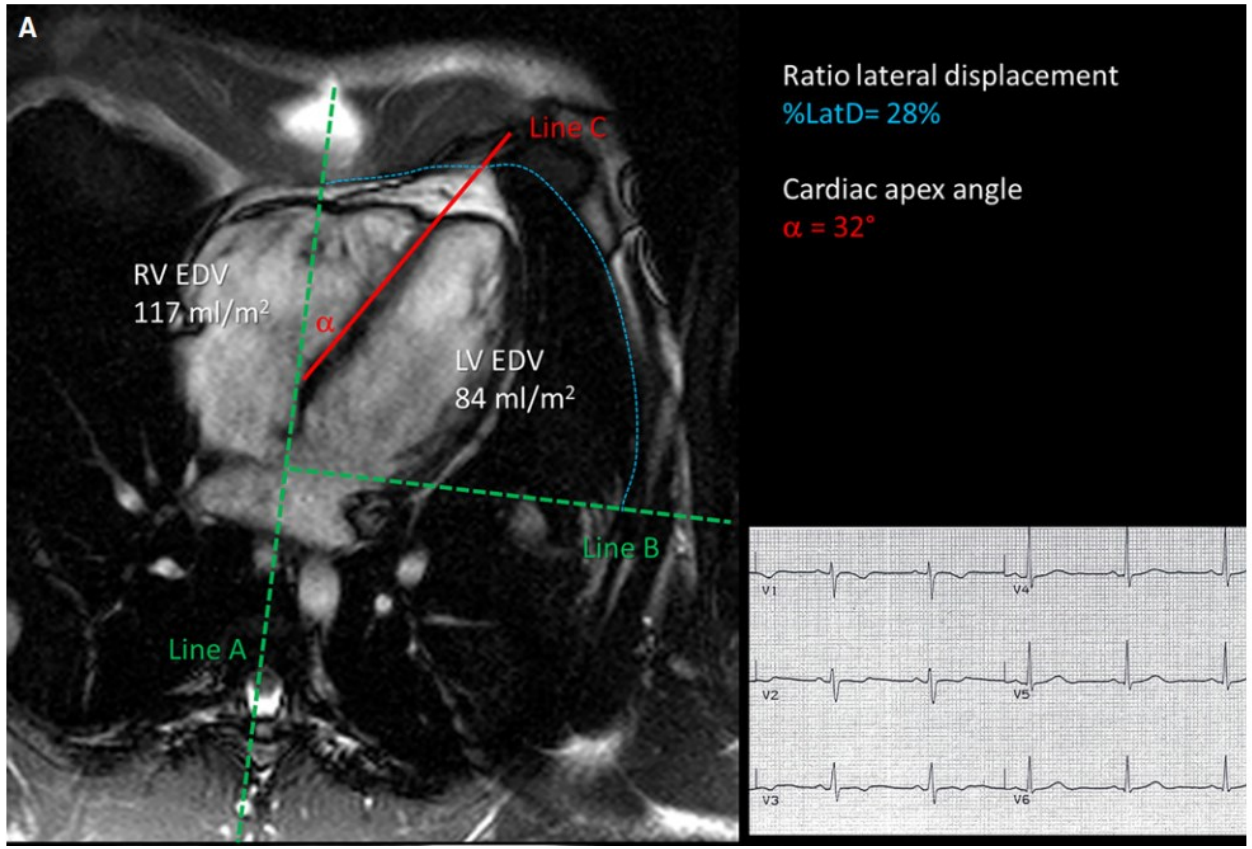

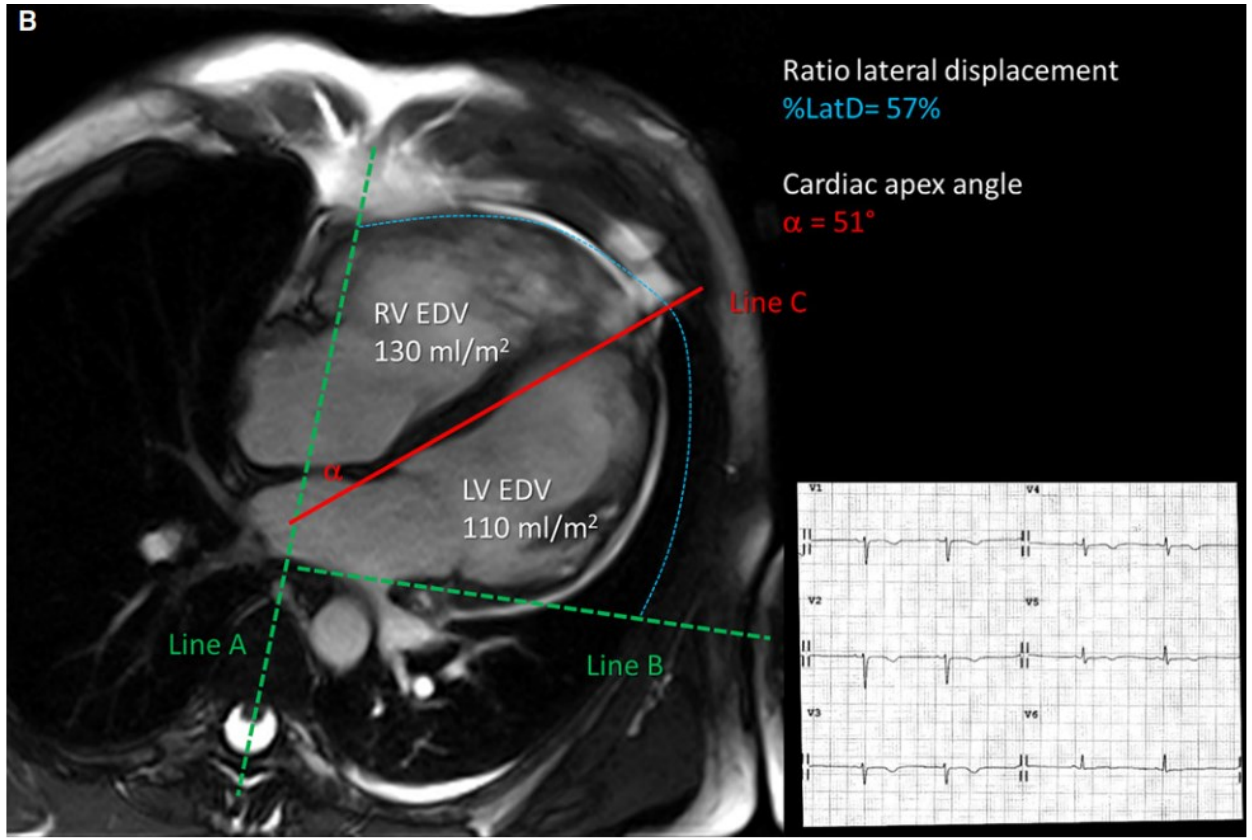

Extent of T-wave inversion in precordial leads predicts RV dilatation & apical displacement

De Lazzari et al., JAHA 2018

Harmful Effects of Exercise in ARC

Lie-Ø et al., JACC EP 2018

n= 173
82 mutation positive family members
91 probands with ACM (TFCriteria2010)

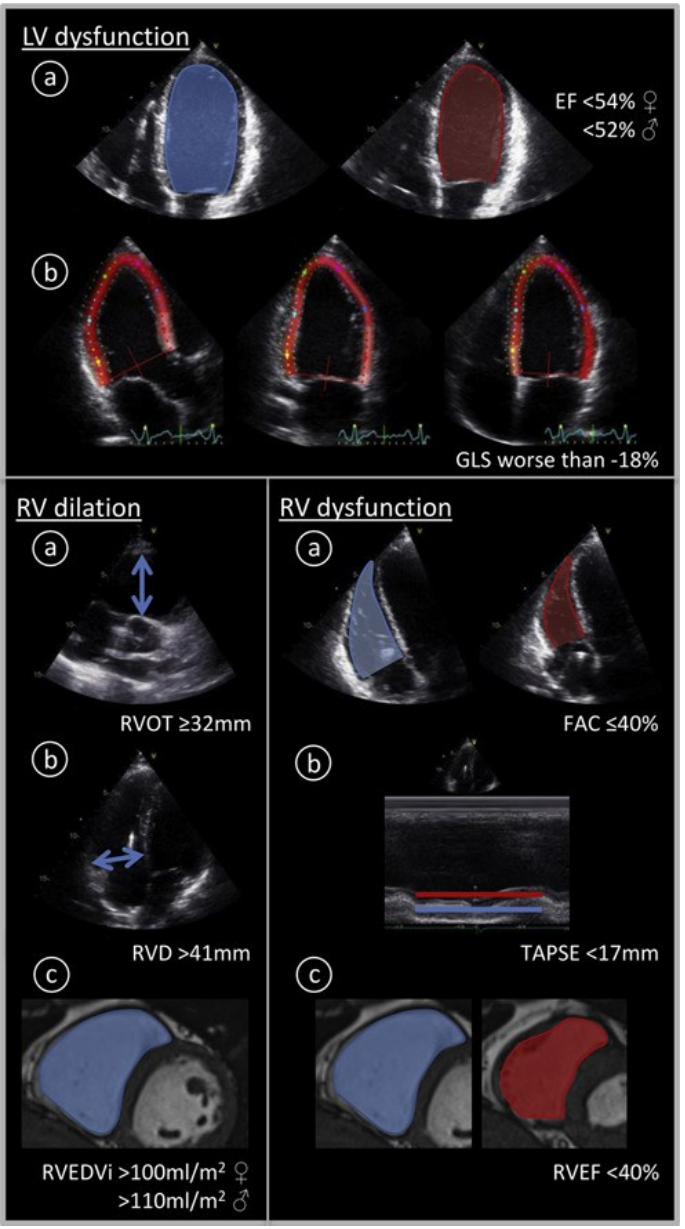

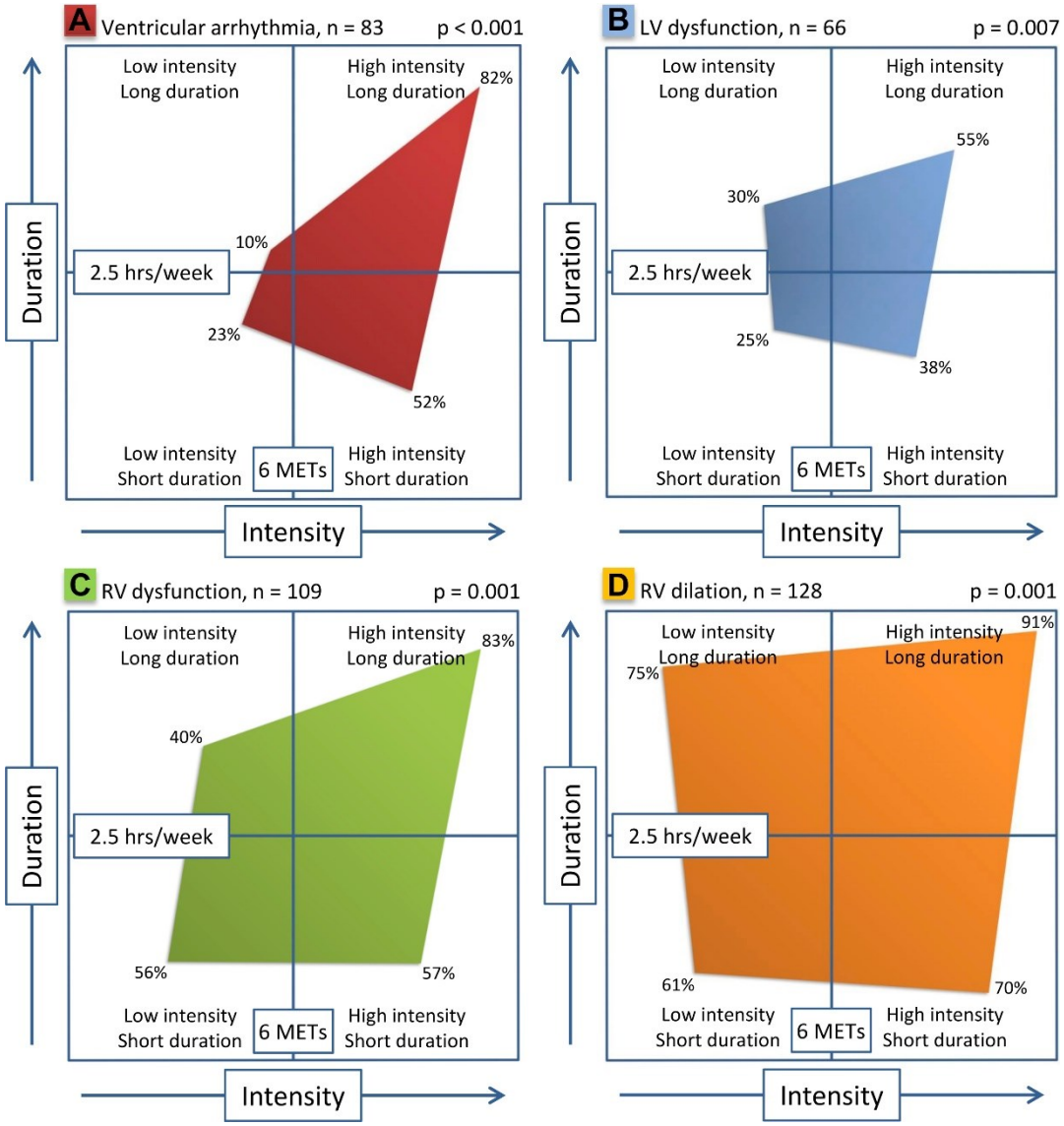

JACC Clin Electrophysiol. 2018 Jun;4(6):744-753

Arrhythmogenic Cardiomyopathy

ECG Features

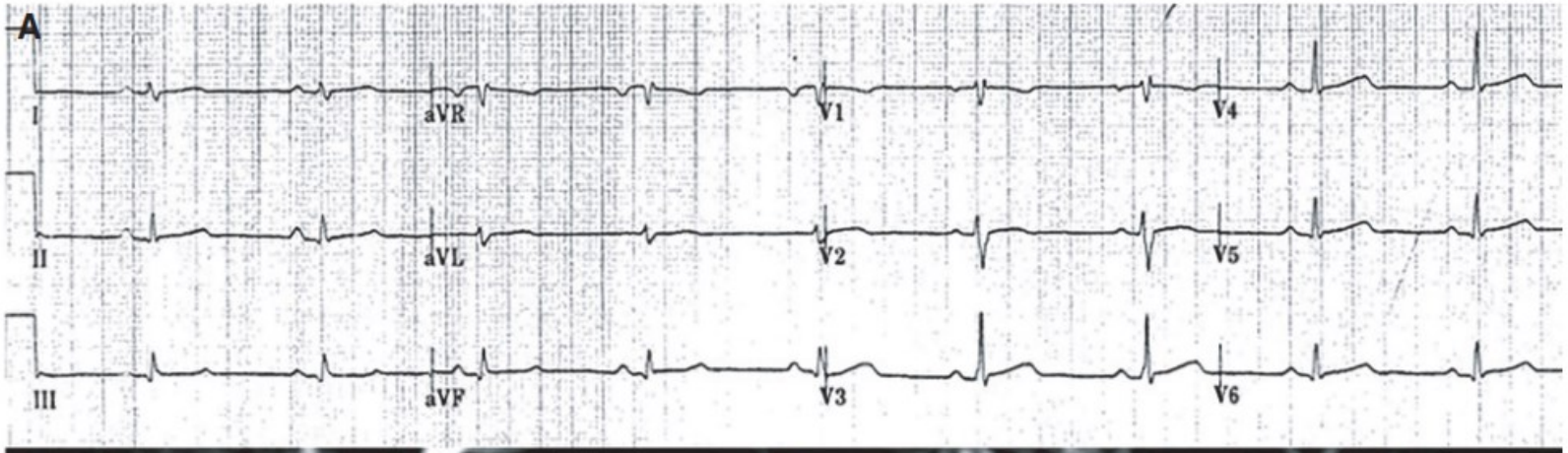

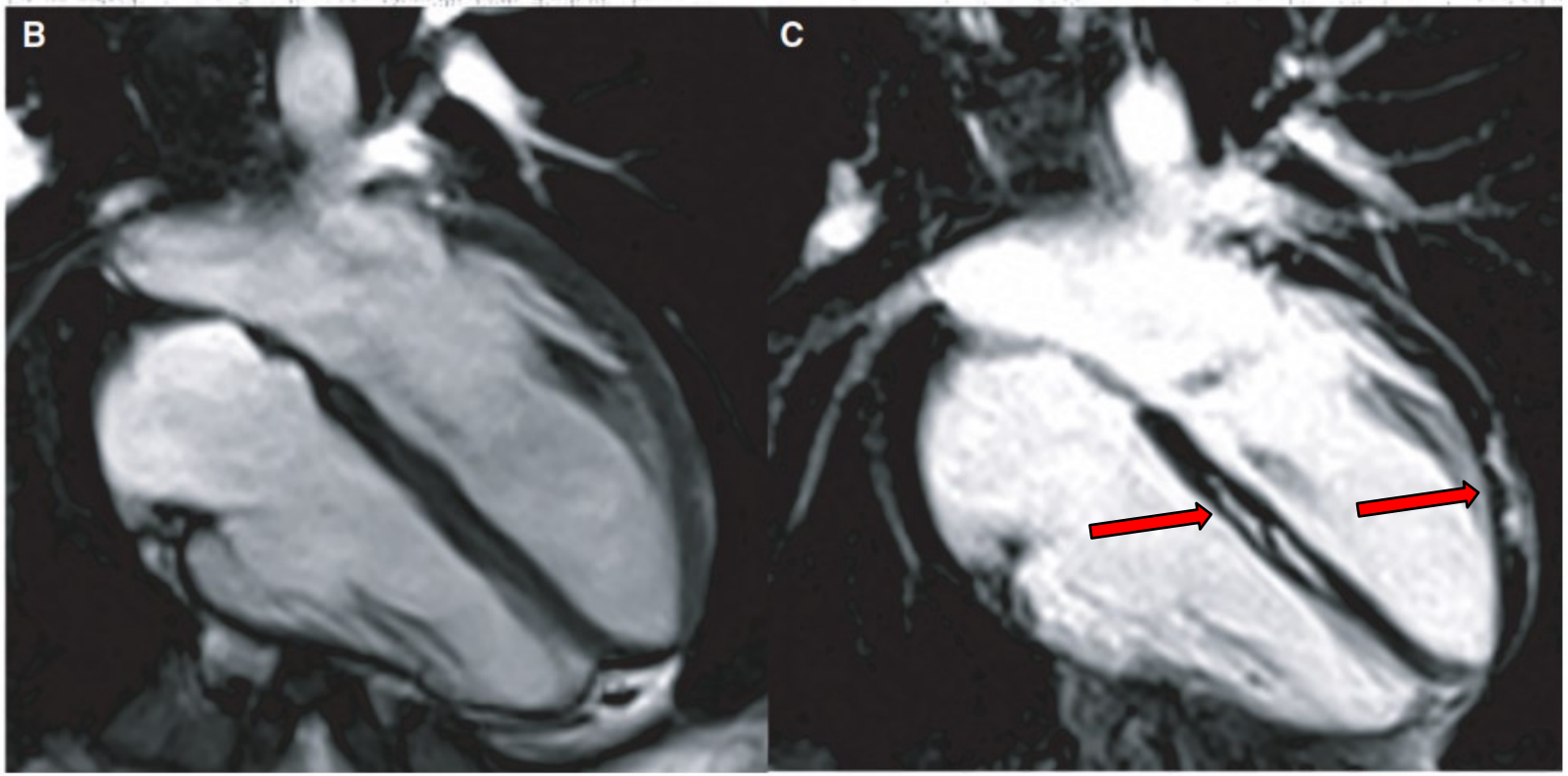

Low-voltage limb leads ≤0,5mV?

➔ ***LV involvement with LV LGE/scar***

De Lazzari et al., JAHA 2018

Arrhythmogenic Cardiomyopathy

ECG Features

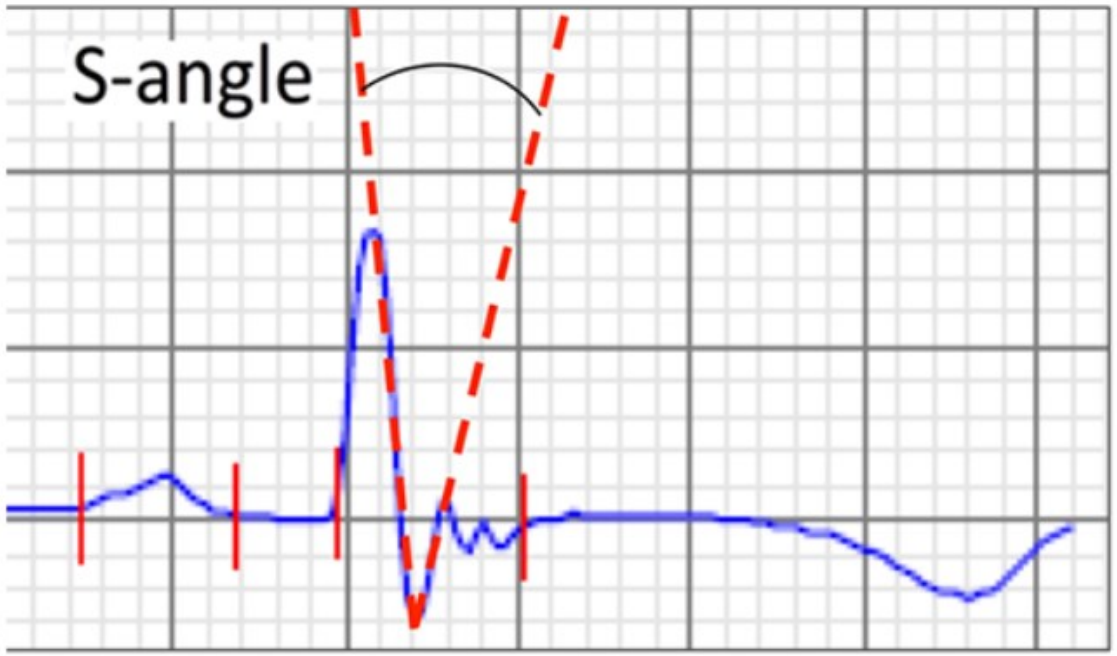

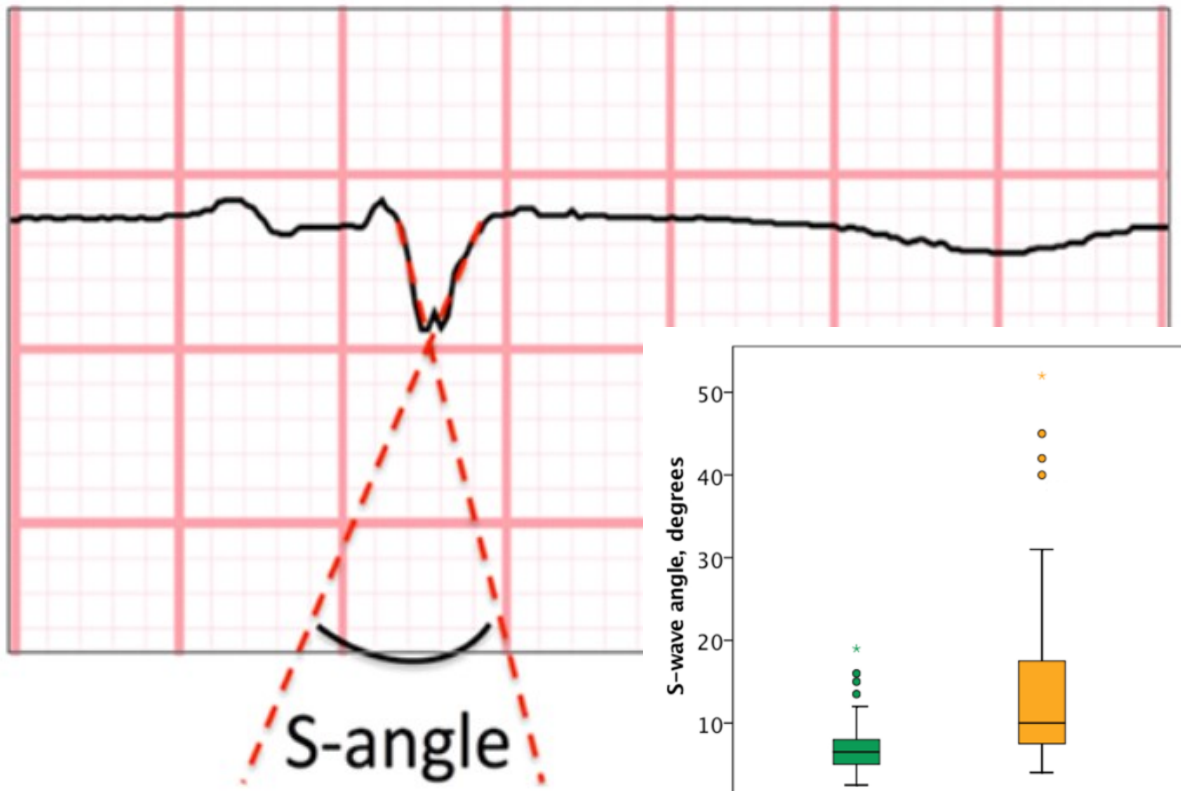

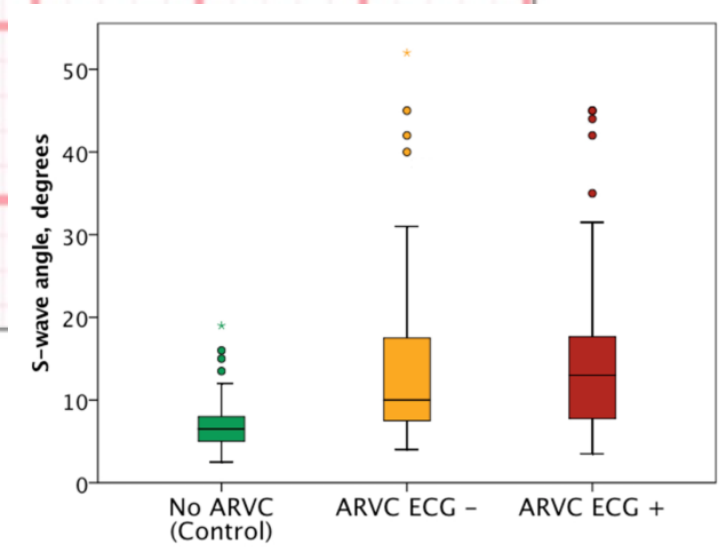

S-wave angle >12,5% identifies ARC

➔ spec 97%, sens 47%, neg pred value 65%

Cortez-D et al., J Electrocard 2018

Recommendations for physical activity in ARC

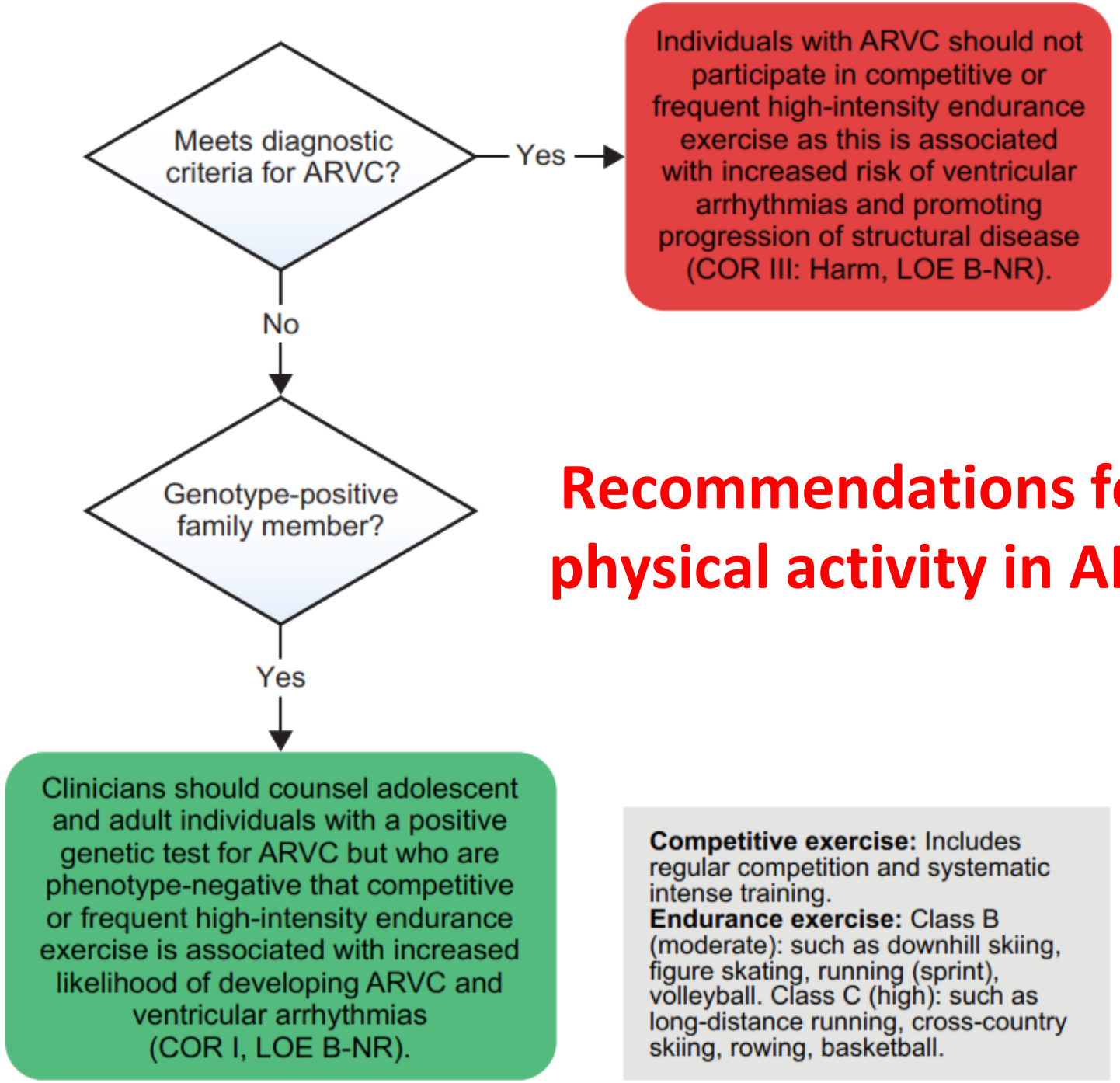

Competitive exercise: Includes regular competition and systematic intense training.
Endurance exercise: Class B (moderate): such as downhill skiing, figure skating, running (sprint), volleyball. Class C (high): such as long-distance running, cross-country skiing, rowing, basketball.

Towbin-JA et al., HRS Consensus ARC, Heart Rhythm 2019

Structural Progression Implies **Clinical** Progression!

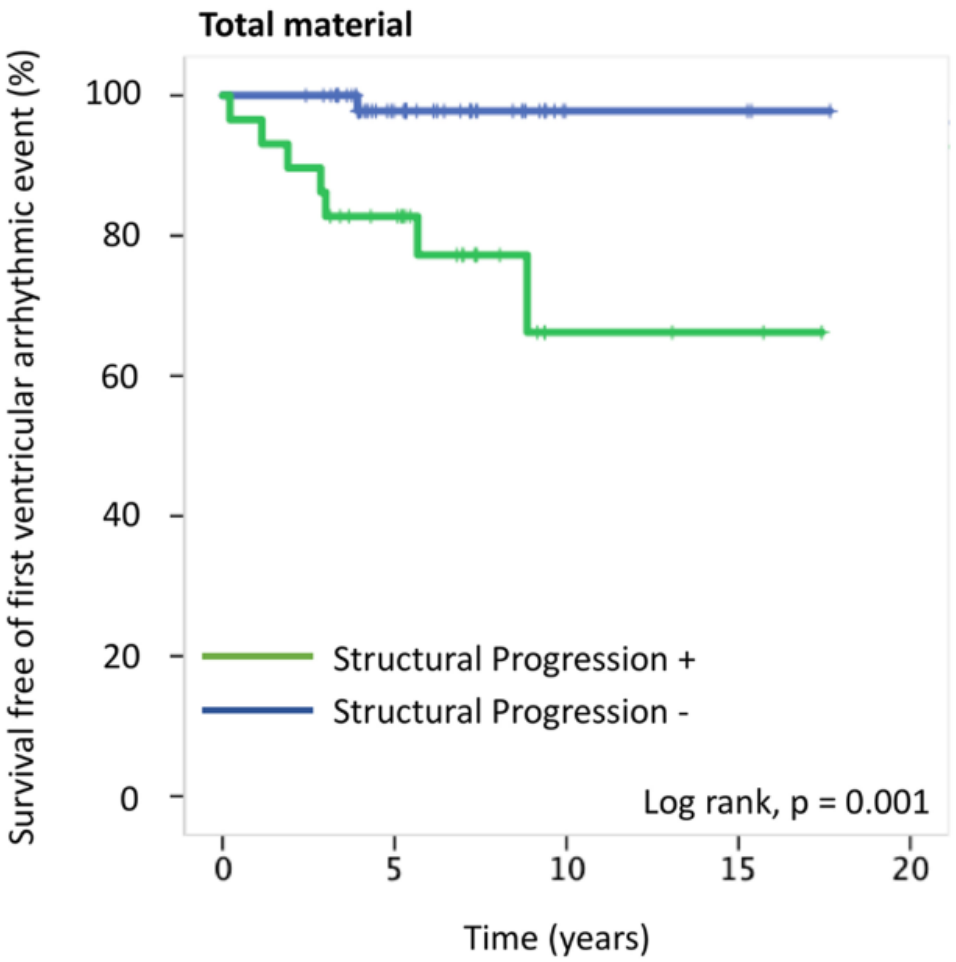

Number at risk				
29	20	3	2	0
57	31	3	3	0

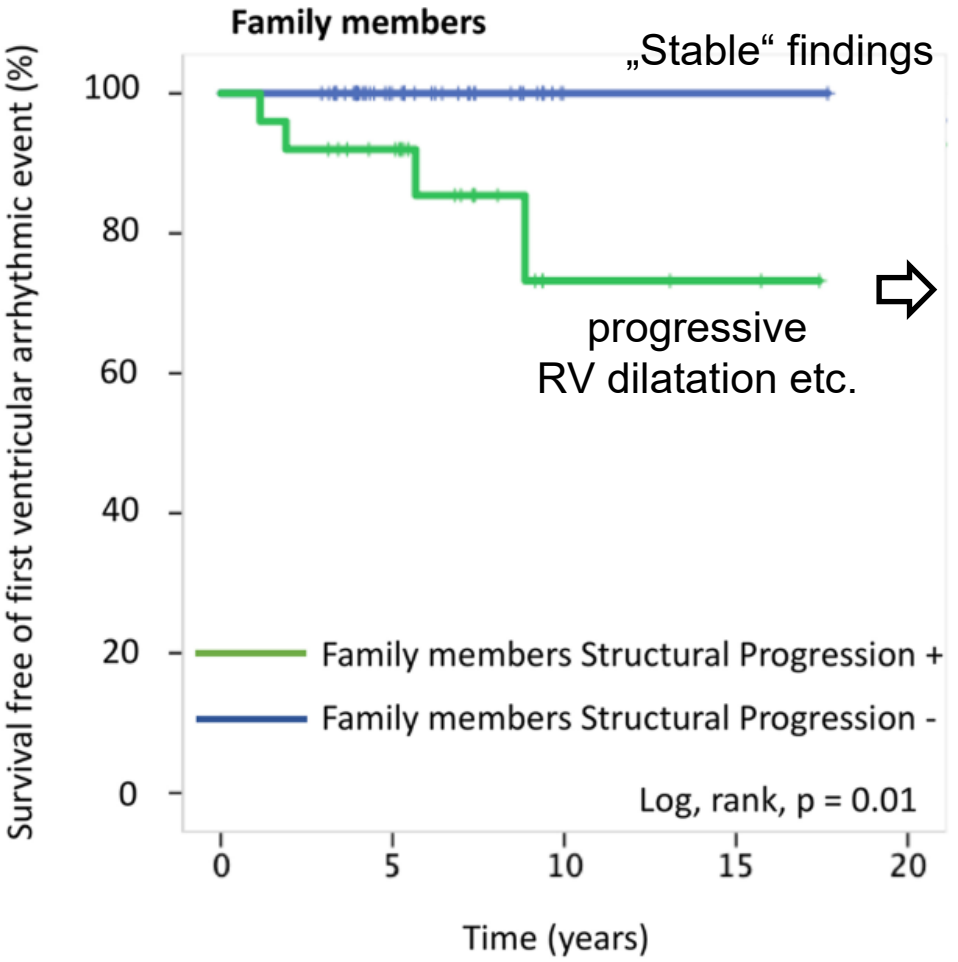

Number at risk				
25	19	3	2	0
48	26	1	1	0

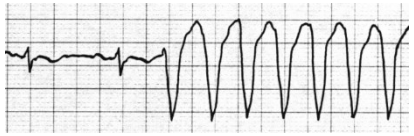

Chivulescu-M et al., Eur Heart J 2019

Arrhythmogenic Cardiomyopathy

Pivotal Role of Plakophilin 2 (PKP2)

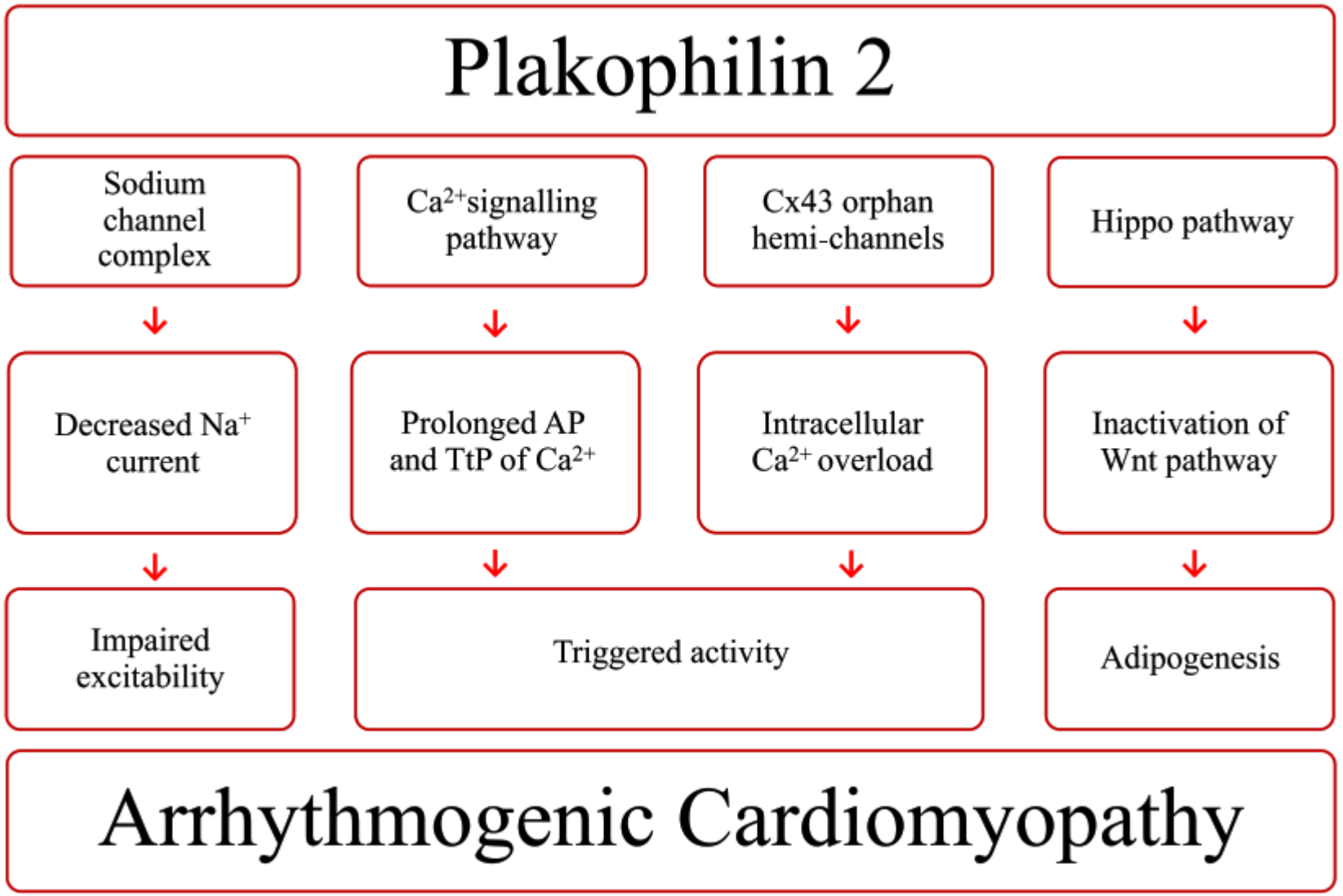

Costa-S et al., Trends CV Medicine 2020 (epub)

Genetisch positive Familienangehörige

Alter bei Diagnosestellung der Erkrankung

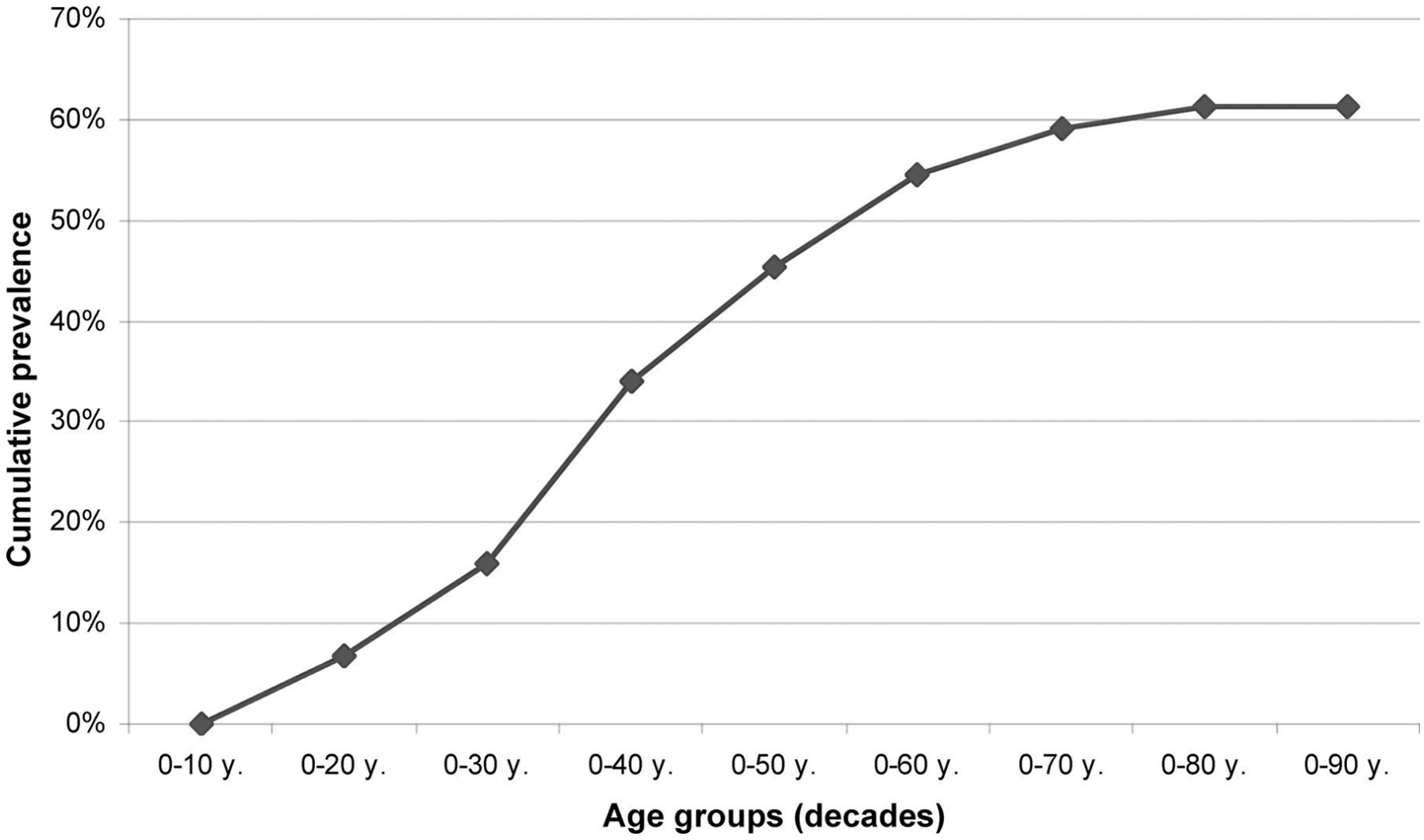

Quarta-G et al., Circ 2011

Arrhythmogenic Cardiomyopathy

HRS Recommendations for *Family Screening*

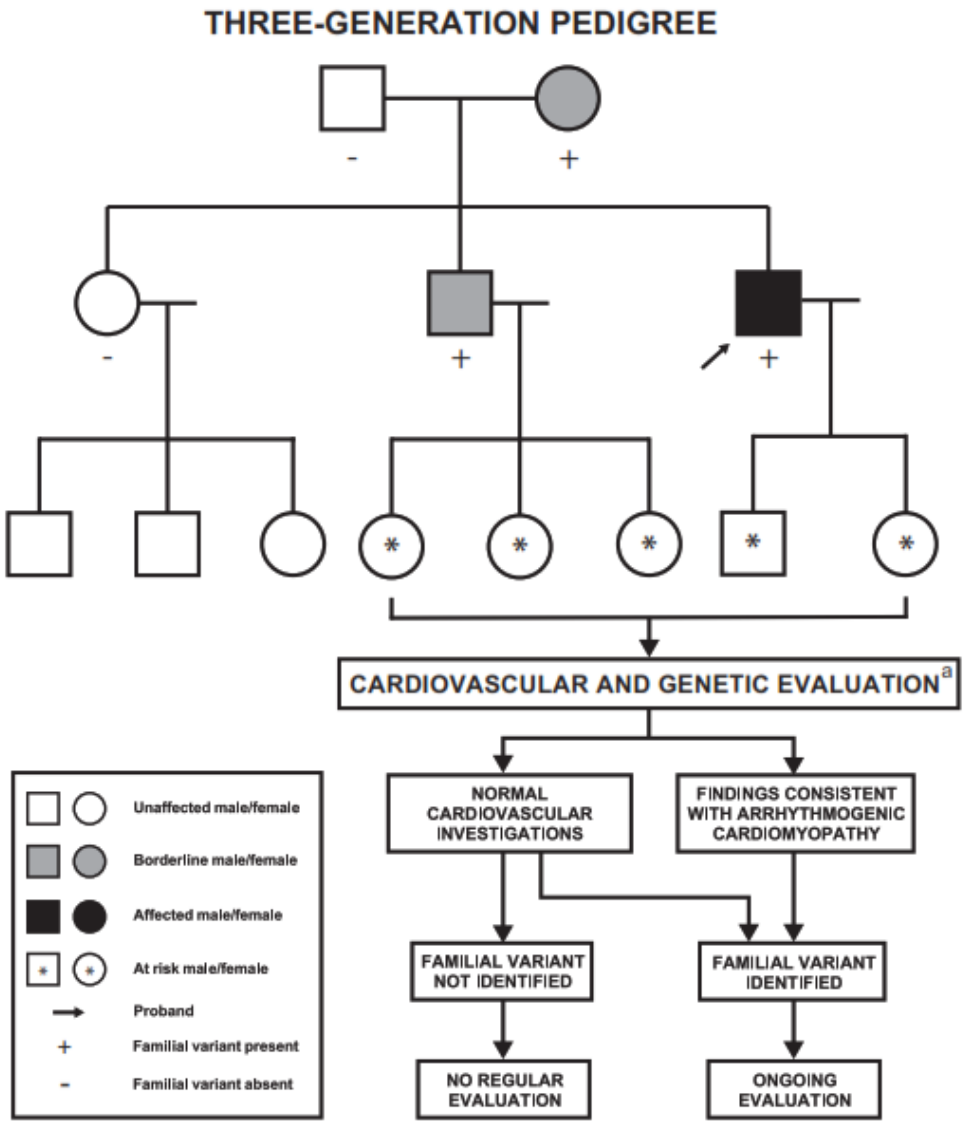

It is recommended that a genetic counselor or appropriately experienced clinician obtain a comprehensive 3-generation family history (COR I, LOEC-EO).

It is recommended that first-degree relatives undergo clinical evaluation every 1–3 years[b] starting at 10–12 years of age[c] (COR I, LOE B-NR).

Cardiovascular evaluation should include 12-lead ECG, ambulatory ECG, and cardiac imaging (COR I, LOE B-NR).

Exercise stress testing (arrhythmia provocation) may be considered as a useful adjunct to cardiovascular evaluation (COR IIb, LOE C-LD).

In families with a variant classified as pathogenic, it may be reasonable for asymptomatic members of a family who do not have the familial variant and have a normal cardiovascular evaluation to be released from regular screening and educated to return if disease symptoms occur (COR IIb, LOE C-EO).

a. The use of genetic testing assumes prior identification of a pathogenic variant in the proband.
b. May vary with age, lifestyle, and family history.
c. Unless family history of disease suggests potential for earlier onset or presence of pathogenic variant in family supports presymptomatic genetic testing.

Towbin-JA et al., HRS Consensus ARC, Heart Rhythm 2019

Disease Progression in ARVD/C

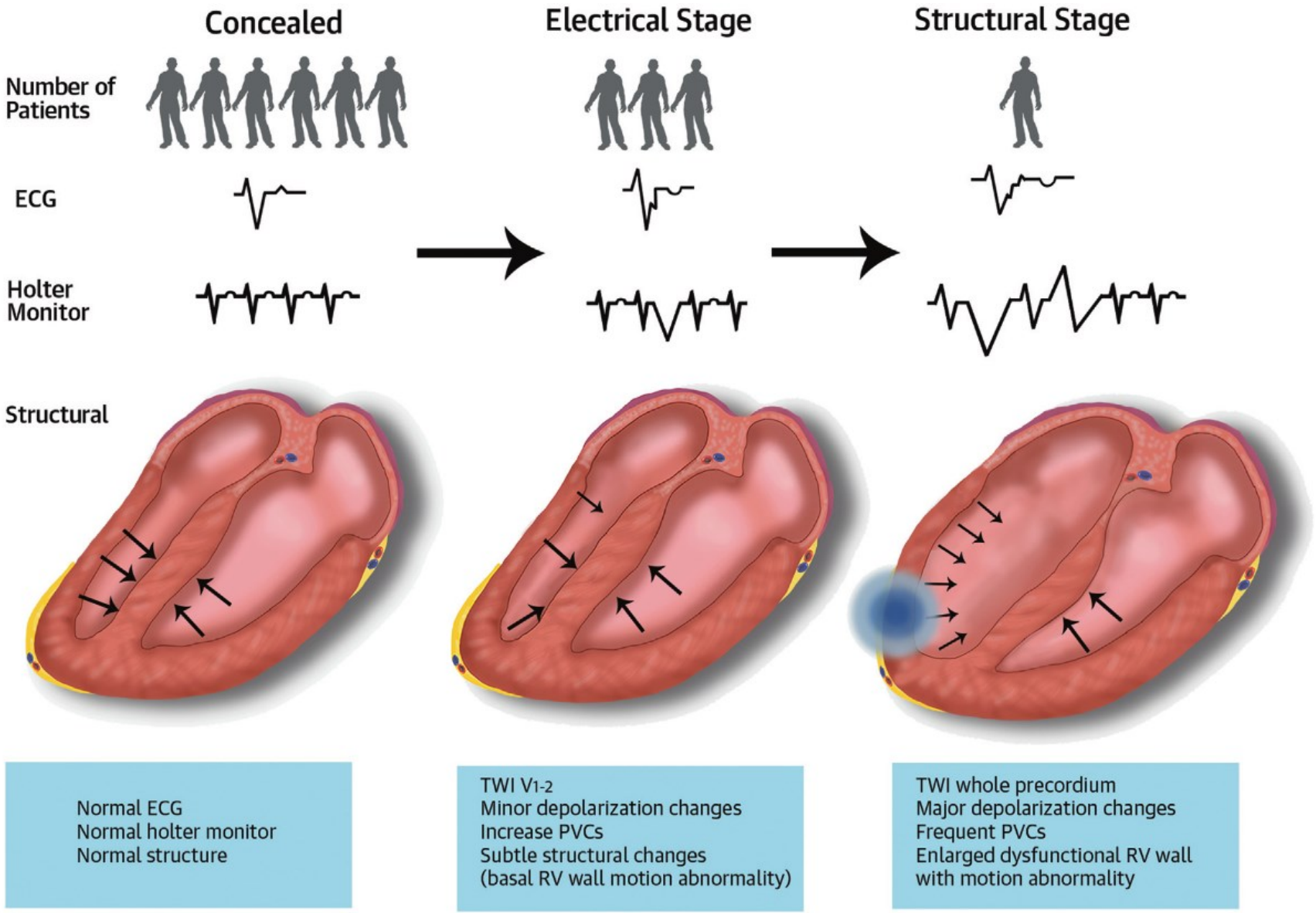

te Riele et al., J Am Coll Cardiol 2014

Arrhythmogenic Cardiomyopathy

Association of Genetic Variants with Phenotypes

AGAPLESION
Unsere Werte verbinden

Genotype	Phenotype
Desmosomal	ARVC/ALVC, hair/skin abnormalities
Lamin A/C	Conduction disease, ventricular arrhythmia/sudden death, DCM, lipodystrophy, muscular dystrophy
SCN5A	Brugada syndrome, conduction disease, AF, VT/VF, DCM
PLN	Low-voltage ECG, VT/VF, DCM, HCM, ARVC
TMEM43	Sudden death M >F, DCM
FLNC	Sudden death, DCM
RBM20	DCM, AF; ventricular arrhythmia/sudden death uncommon as an early feature
Desmin	Skeletal myopathy, DCM; arrhythmia uncommon as an early feature

Towbin-JA et al., HRS Consensus ARC, Heart Rhythm 2019

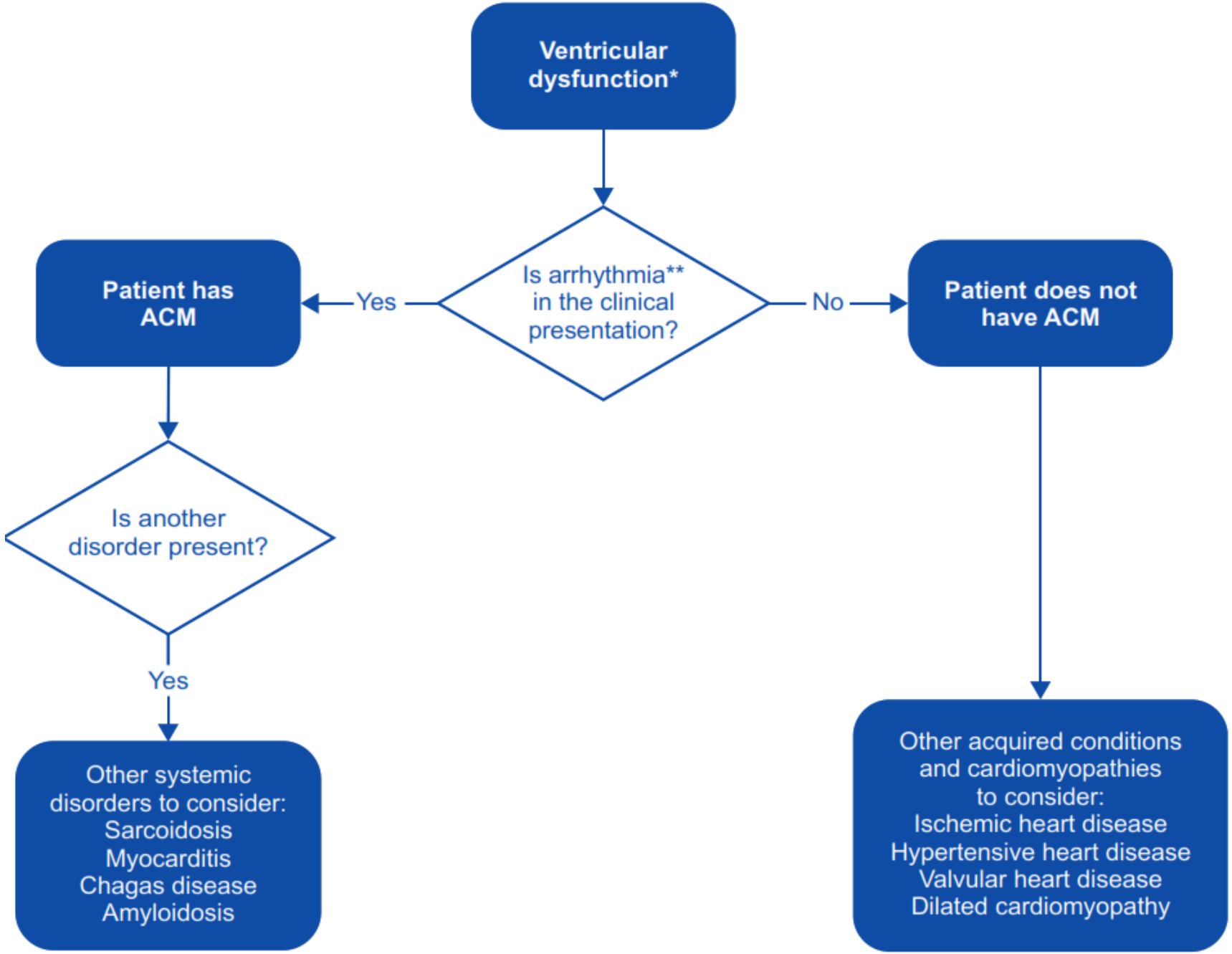

*Not explained by ischemic, hypertensive, or valvular heart disease
**Arrhythmia includes conduction disease, atrial arrhythmias, ventricular arrhythmias

Towbin-JA et al., HRS Consensus ARC, Heart Rhythm 2019

ARRHYTHMOGENIC CARDIOMYOPATHY

HISTOPATHOLOGY

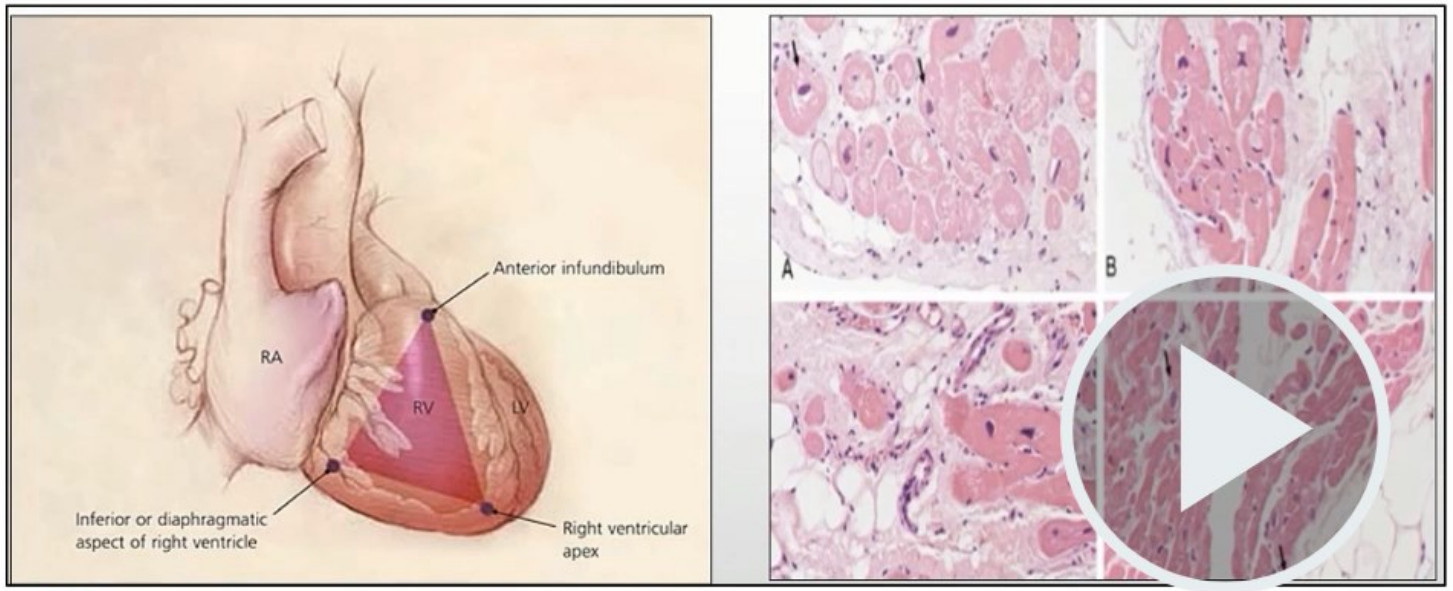

- Main sites affected: posterior RV free wall, RV outflow tract and apex: Triangle of ARVC
- Diffuse variants affecting LV have inferolateral predominance: Quadrangle of ARVC

Basso C et al. Lancet 2009;373: 1289-1300

ARRHYTHMOGENIC CARDIOMYOPATHY

DIAGNOSTIC CRITERIA

BASED ON THE FOLLOWING FEATURES:

- Structural
- Histological
- Arrhythmic
- Familiar

.Marcus FI, McKenna WJ, Sherrill D, Basso C, Ba
arrhythmogenic right ventricular cardiomyopathy
Task Force criteria. Eur Heart J. 2010; 31:806-14

ARRHYTHMOGENIC CARDIOMYOPATHY

DIAGNOSTIC CRITERIA

- **Definite:**
  - 2 major criteria
  - 1 major criteria and 2 minor criteria
  - 4 minor criteria

  Different categories
- **Borderline:**
  - 1 major criteria and 1 minor
  - 3 minor criteria

  Different categories
- **Possible:**
  - 1 major criteria
  - 2 minor criteria

  Different categories

.Marcus FI, McKenna WJ, Sherrill D, Basso C, Bauce B, Bluemke DA, et al. Diagnosi
criteria. Eur Heart J. 2010; 31:806-14.

ARRHY

International TASK FORCE

ARRHYTHMOGENIC CARDIOMYOPATHY

DIAGNOSTIC IMAGING

- Hypokinesis is not included in this or subsequent definitions of RV regional wall motion abnormalities
- LV disturbance is a sub –set of ARVC and leads to poor prognosis
- Late gadolinium uptake and fatty replacement are diagnostic useful

Criterios diagnosticos para la miocardiopatıa arritmogenica del ventrıculo derecho Diagnostic Criteria for Arrhythmogenic Right Ventricular Cardiomyopathy Rev Esp Cardiol. 2012;65

Table 1. Comparison of Original and Revised Task Force Criteria

Original Task Force Criteria	Revised Task Force Criteria
I. Global or regional dysfunction and structural alterations*	
Major	
• Severe dilatation and reduction of RV ejection fraction with no (or only mild) LV impairment • Localized RV aneurysms (akinetic or dyskinetic areas with diastolic bulging) • Severe segmental dilatation of the RV	**By 2D echo:** • Regional RV akinesia, dyskinesia, or aneurysm • *and* 1 of the following (end diastole): — PLAX RVOT ≥32 mm (corrected for body size [PLAX/BSA] ≥19 mm/m²) — PSAX RVOT ≥36 mm (corrected for body size [PSAX/BSA] ≥21 mm/m²) — *or* fractional area change ≤33% **By MRI:** • Regional RV akinesia or dyskinesia or dyssynchronous RV contraction • *and* 1 of the following: — Ratio of RV end-diastolic volume to BSA ≥110 mL/m² (male) or ≥100 mL/m² (female) — *or* RV ejection fraction ≤40% **By RV angiography:** • Regional RV akinesia, dyskinesia, or aneurysm
Minor	
• Mild global RV dilatation and/or ejection fraction reduction with normal LV • Mild segmental dilatation of the RV • Regional RV hypokinesia	**By 2D echo:** • Regional RV akinesia or dyskinesia • *and* 1 of the following (end diastole): — PLAX RVOT ≥29 to <32 mm (corrected for body size [PLAX/BSA] ≥16 to <19 mm/m²) — PSAX RVOT ≥32 to <36 mm (corrected for body size [PSAX/BSA] ≥18 to <21 mm/m²) — *or* fractional area change >33% to ≤40% **By MRI:** • Regional RV akinesia or dyskinesia or dyssynchronous RV contraction • *and* 1 of the following: — Ratio of RV end-diastolic volume to BSA ≥100 to <110 mL/m² (male) or ≥90 to <100 mL/m² (female) — *or* RV ejection fraction >40% to ≤45%

107 of 224 positive on genetic testing

169 M, 55 F; mean age 41±15y

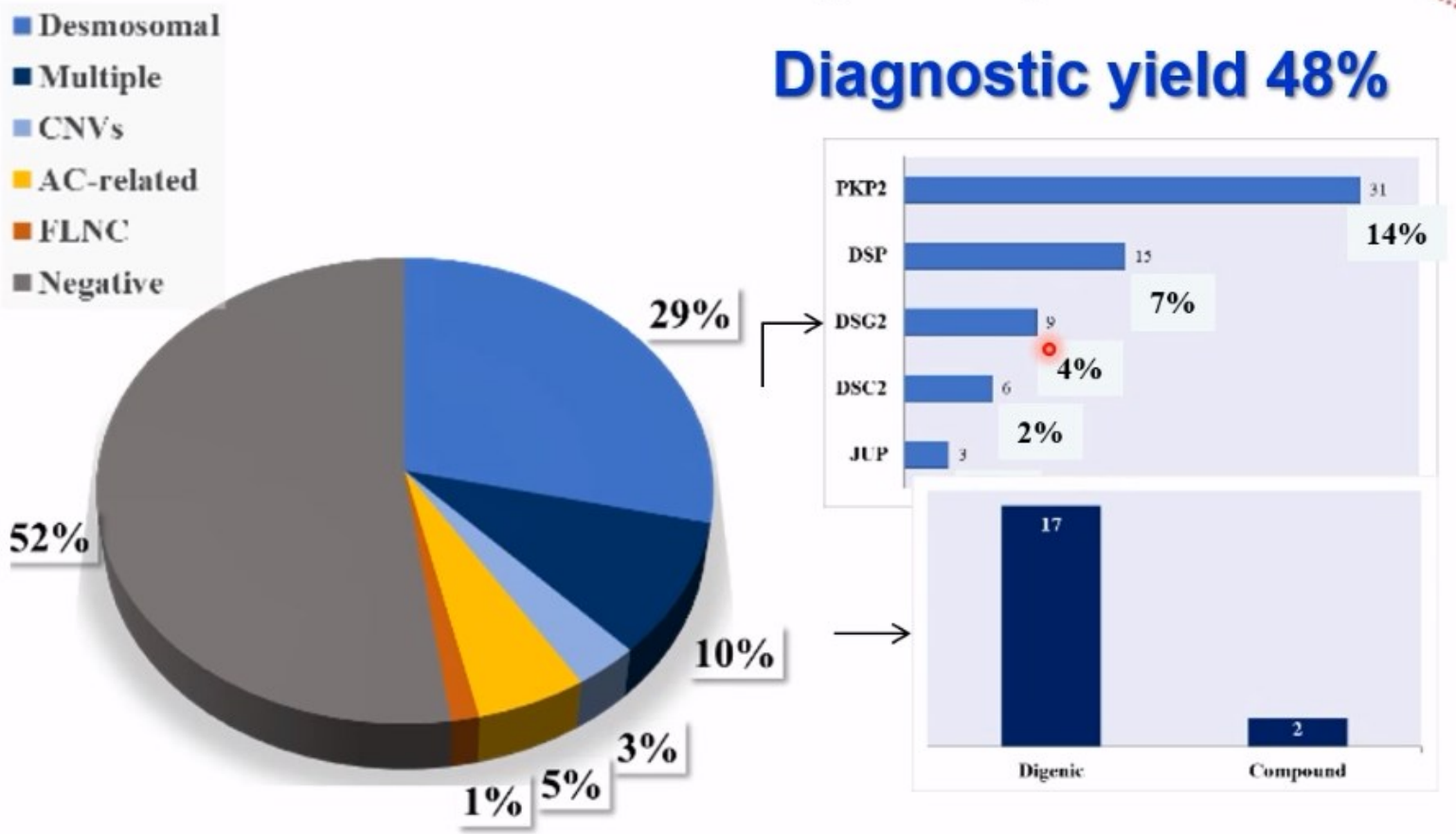

No differences in clinical outcome in pts with different Desmosomal mutations
Multiple mutations= severe forms of the disease
DSP mutations: prevalence of «left dominant phenotype»
Identification of variants of uncertain significance (VUS)

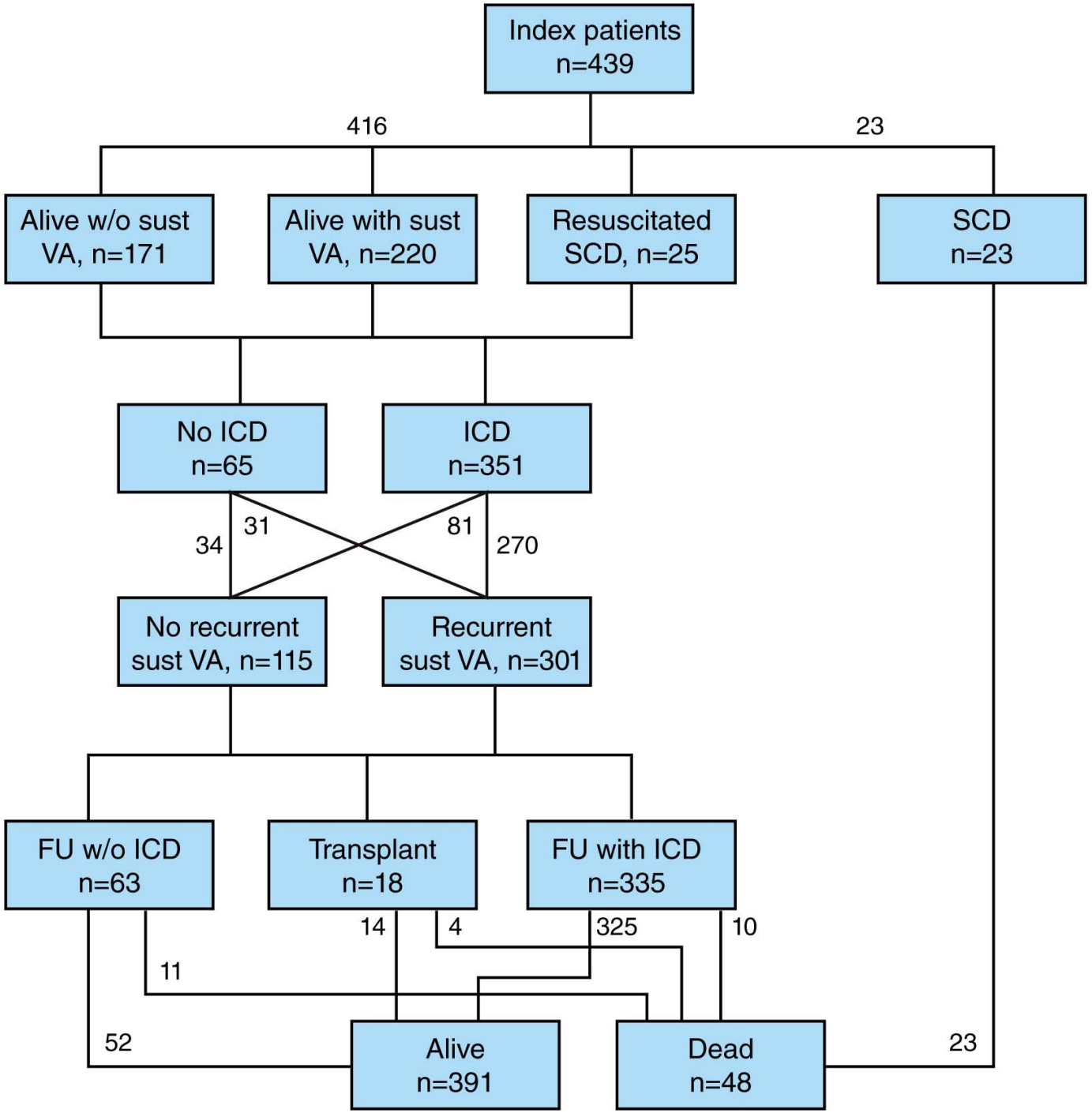

Groeneweg-J et al., Circ Genetics 2015
Calkins-H, Circulation J 2015; 901-913

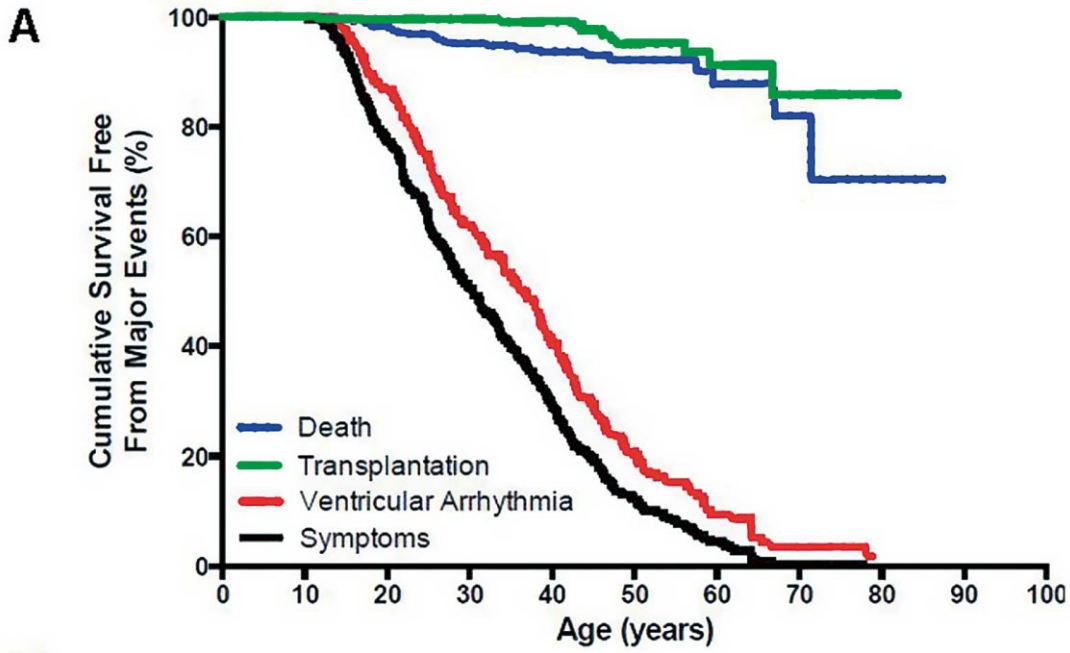

Number at risk											
Death	264	264	253	209	161	94	35	8	1	0	0
Transplantation	264	264	253	209	161	94	35	8	1	0	0
Ventricular arrhythmia	264	264	229	159	99	44	13	2	0	0	0
Symptoms	264	264	206	137	79	33	11	1	0	0	0

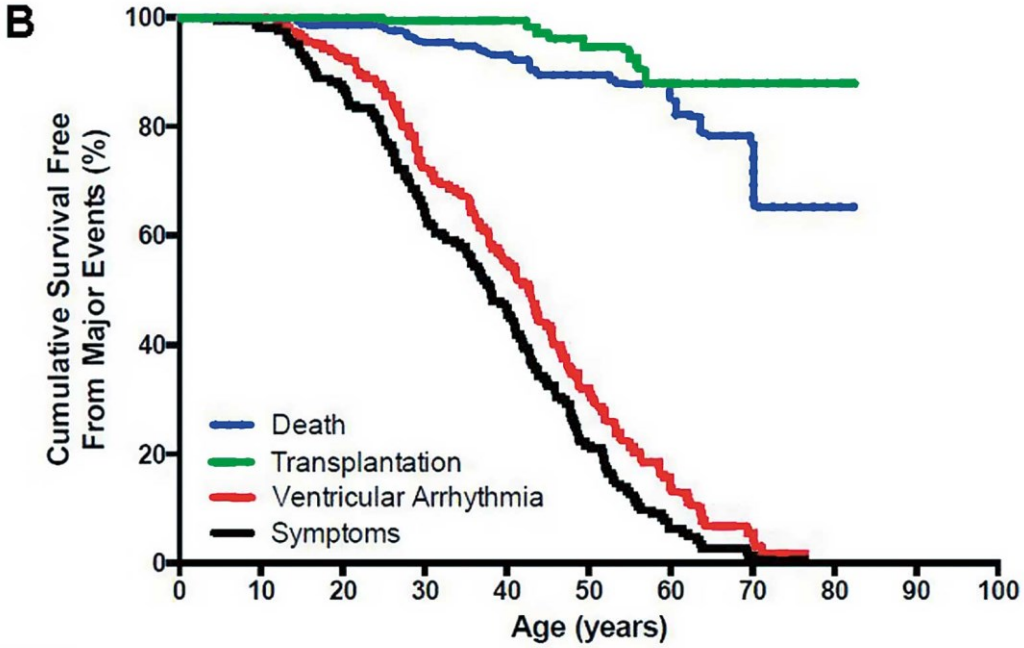

Number at risk											
Death	152	152	149	132	107	66	28	5	2	0	0
Transplantation	152	152	149	132	107	63	24	5	2	0	0
Ventricular arrhythmia	152	152	141	106	80	38	13	2	0	0	0
Symptoms	152	149	132	97	70	31	7	1	0	0	0

Groeneweg-J et al., Circ Genetics 2015
Calkins-H, Circulation J 2015; 901-913

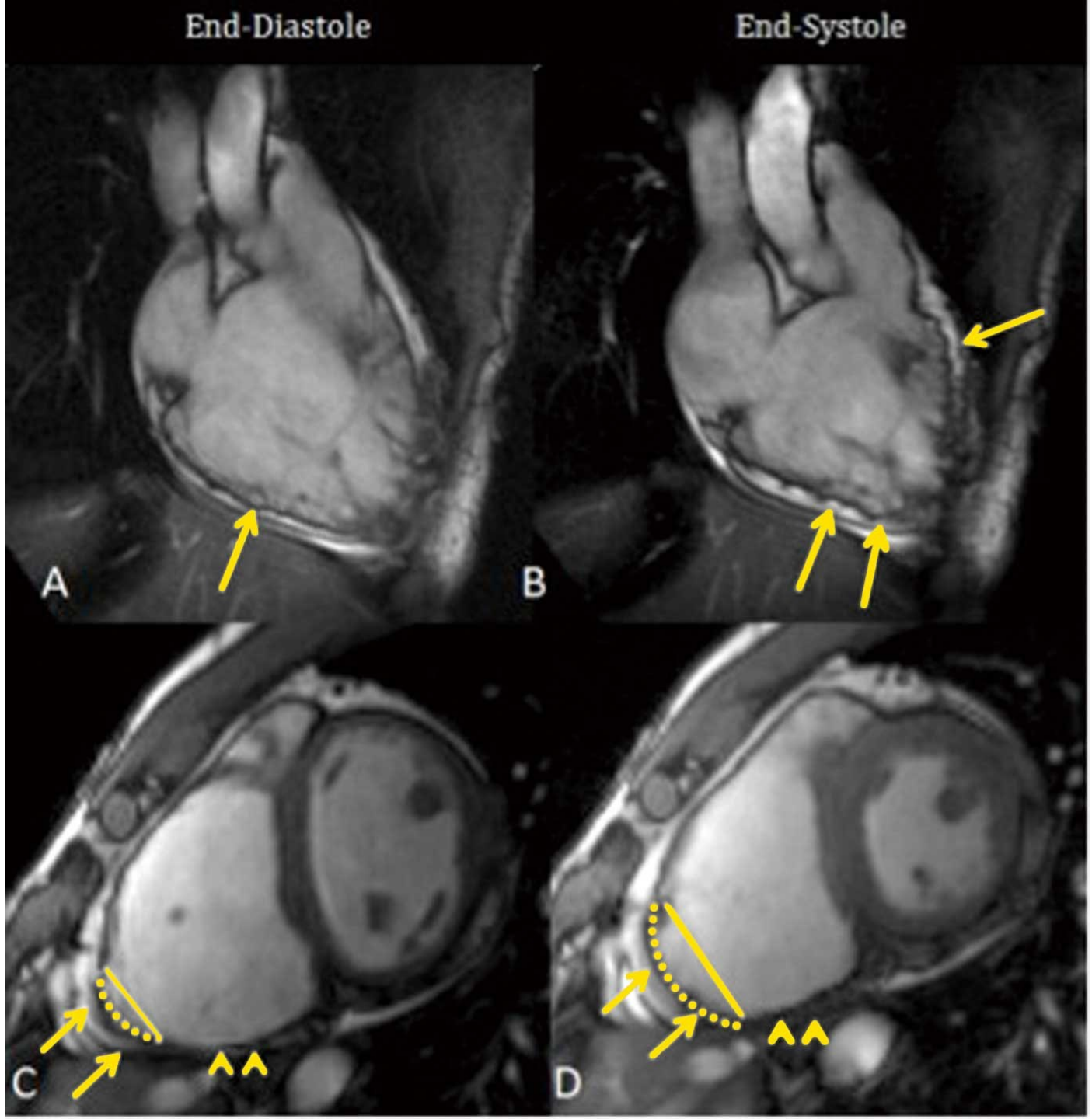

Calkins-H, Circulation J 2015; 901-913

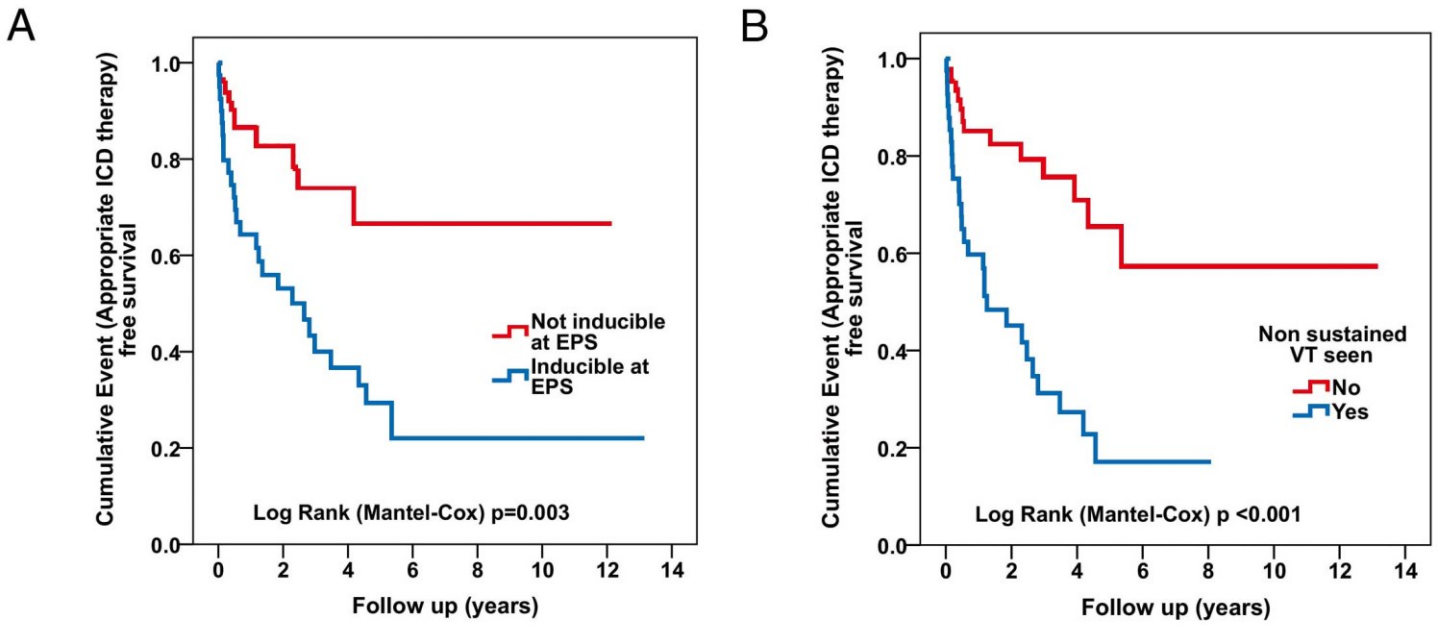

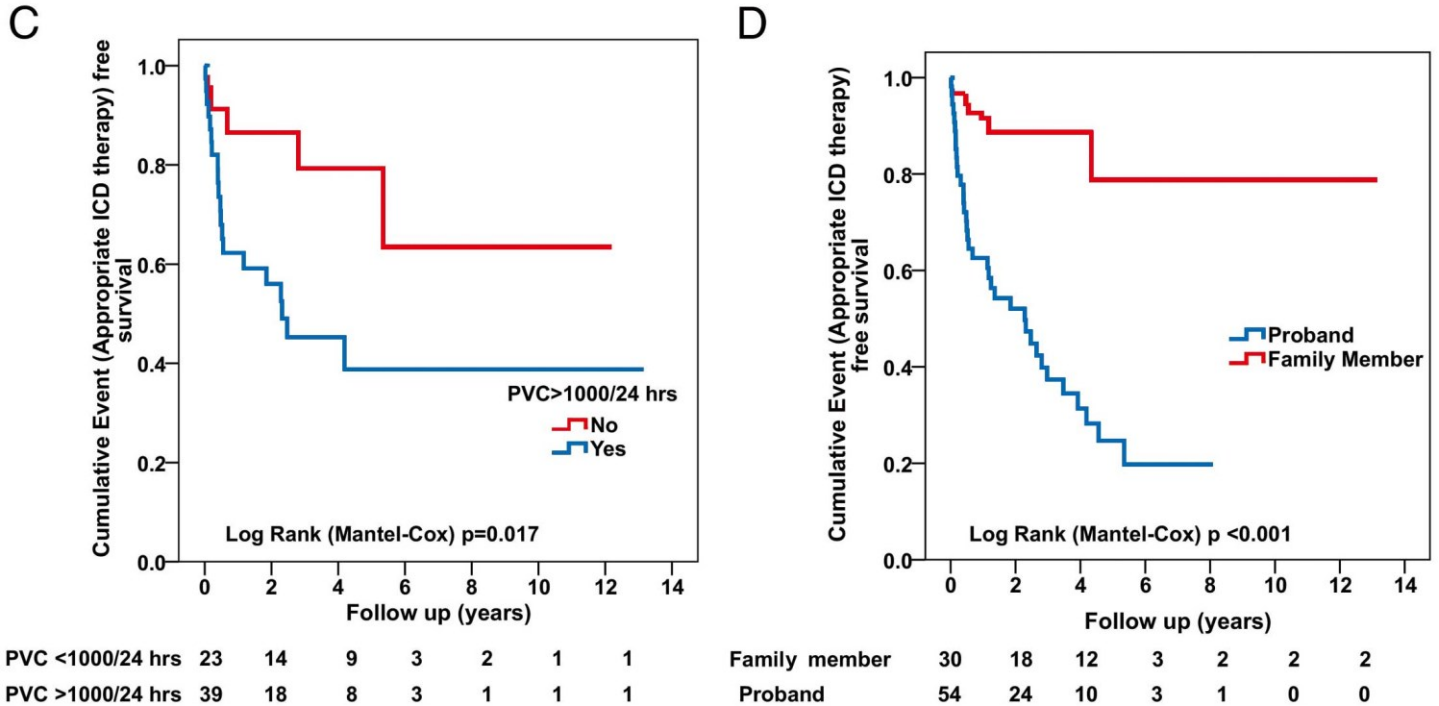

Bhonsale-A et al., J Am Coll Cardiol 2011
Calkins-H, Circulation J 2015; 901-913

Table. 2010 Task Force Criteria for ARVD/C*

1 Global or regional dysfunction and structural alterations
Major
2nd echo criteria
Regional RV akinesia, dyskinesia, or aneurysm AND 1 of the following measured at end diastole
PLAX RVOT ≥32 mm or
PSAX RVOT ≥36,
Fractional area change ≤33%
MRI criteria
Regional RV akinesia or dyskinesia or dyssynchronous RV contraction AND 1 of the following
Ratio of RV end-diastolic volume to BSA ≥100, 110 ml/m^2 (male) or ≥100 ml/m^2
RV ejection fraction >40% ≤45%
RV angiography criteria
Regional RV akinesia, dyskinesia, or aneurysm
Minor
2nd echo criteria
Regional RV akinesia or dyskinesia or dyssynchronous RV contraction AND 1 of the following measured at end diastole
PLAX RVOT ≥29 <32 mm or
PSAX RVOT ≥32 <36
Fractional area change >33% ≤40%
MRI criteria
Regional RV akinesia or dyskinesia or dyssynchronous RV contraction AND 1 of the following
Ratio of RV end-diastolic volume to BSA ≥110 ml/m^2 (male) or ≥100 ml/m^2
RV ejection fraction ≤40%
2 Tissue characterization of wall
Major
Residual myocytes <60% by morphometric analysis (or <50% if estimated), with fibrous replacement of the RV free wall myocardium in ≥1 sample,
with or without fatty replacement of tissue on endomyocardial biopsy
Minor
Residual myocytes 60–75% by morphometric analysis (or 50–65% if estimated), with fibrous replacement of the RV free wall myocardium in ≥1 sample
with or without fatty replacement of tissue on endomyocardial biopsy
3 Repolarization abnormalities
Major
Inverted T waves in right precordial leads (V1, V2, and V3) or beyond in individuals >14 years of age (in the absence of complete RBBB QRS ≥120 ms)
Minor
Inverted T waves in V1 and V2 in individuals >14 years of age (in the absence of complete RBBB) or in V4, V5, and V6
Inverted T waves in leads V1, V2, V3, and V4 in individuals >14 years of age in the presence of a complete RBBB
4 Depolarization/conduction abnormalities
Major
Epsilon wave (reproducible low-amplitude signals between end of QRS complex to onset of T wave) in the right precordial leads (V1–3)
Minor
Late potentials by SAECG in ≥1 of 3 parameters in the absence of a QRSd ≥110 ms on standard ECG
Filtered QRS duration (fQRS) ≥114 ms
Duration of terminal QRS <40 microV ≥38 ms
Root-mean-square voltage of terminal 40 ms ≤ micro V
Terminal activation duration ≥55 ms measured from the nadir of the end of the QRS, including R', in V1, V2, or V3 in absence of complete RBBB
5 Arrhythmias
Major
Nonsustained or sustained VT of LBBB morphology with superior axis
Minor
Nonsustained or sustained VT of RVOT configuration, LBBB morphology with inferior axis or of unknown axis
>500 PVCs per 24 h (Holter)
6 Family history
Major
ARVD/C in first-degree relative who meets Task Force Criteria
ARVD/C confirmed pathologically at autopsy or surgery in first-degree relative
Identification of pathogenic mutation categorized as associated or probably associated with ARVD/C in the patient under evaluation
Minor
History of ARVD/C in first-degree relative in whom it is not possible to determine whether the family member meets Task Force Criteria
Premature sudden death (<35 years of age) due to suspected ARVD/C in a first-degree relative
ARVD/C confirmed pathologically or by current Task Force Criteria in second-degree relative

*Adapted from Marcus FI, et al.[11] ARVD/C, Arrhythmogenic Right Ventricular Dysplasia/Cardiomyopathy; BSA, body surface area; LBBB, left bundle branch block; PVC, premature ventricular contraction; RBBB, right bundle branch block; RVOT, right ventricular outflow tract; SAECG, signal-averaged ECG; VT, ventricular tachycardia.

Marcus-FI et al., Circulation 2010
Calkins-H, Circulation J 2015; 901-913

CMR Reporting Template for ARVC/D

AGAPLESION
Unsere Werte verbinden

Reporting template "Arrhythmogenic Right Ventricular Cardiomyopathy/Dysplasia – ARVC/D"

(Micro) aneurysms RV wall: no / yes _____ [1]

Right ventricular wall thinning: no / yes _____ [1]

Dyssynchronous RV contraction: no / yes

Optional: *RVOT4 width in 3-chamber view*:_____ mm/m² (normal: xx mm/m²).*

Tissue properties:

Late gadolinium enhancement (LGE) myocardium: no / yes _____ [2]

Evidence of fat signal in myocardium: no / yes _____ [3]

Assessment according to Task Force criteria (revised 2010)[#]:[4]

Major criterion: no / yes

Minor criterion: no / yes

Additional findings

No / yes _____

Conclusion:

MRI indicative of ARVC: no / yes

_____ [5]

► * Eur Heart J Cardiovasc Imaging. 2017 May 26. http://dx.doi.org/10.1093/ehjci/jex092 [33]. # Eur Heart J. 2010;31:806–814. http://dx.doi.org/10.1093/eurheartj/ehq025 [18]. [1] Localization. Typical locations are the "triangle of dysplasia": RV wall adjacent to the RV inflow and outflow path and the apex of the heart [18] or the basal anterior and inferior RV wall as well as the posterolateral LV wall [27]. [2] Localization according to 17-segment model [26] or inclusion of the RV analogously to the 5-segment model [27] and indication of the distribution pattern (subendocardial/intramyocardial/subepicardial/transmural). [3] Localization: Typical features are focal, myocardial fatty degeneration or an "infiltrative", finger-shaped fatty degeneration of the free RV wall progressing from the epicardium with myocardial wall thinning potentially associated with late gadolinium enhancement [34]; MR tomographic fat detection or late gadolinium enhancement are not part of the Task Force criteria [18]. [4] Only one major or minor criterion can be derived from MR imaging alone [18]. The definitive diagnosis of ARVD requires the presence of at least 2 major criteria, 1 major criterion plus 2 minor criteria or 4 minor criteria from 6 different diagnostic categories; a definitive diagnosis cannot be made based solely on MR diagnostics. A "borderline" ARVD is based on evidence of one major plus one minor criterion or 3 minor criteria. A "possible" ARVD is based on evidence of one major criterion or two minor criteria. **The MR criteria are defined as follows:** *Major criterion:* Regional RV akinesia or dyskinesia or dyssynchronous RV contraction and presence of one of the following findings: Ratio of RV EDV to BSA ≥ 110 mL/m²(male) or ≥ 100 mL/m² (female) *or* RV ejection fraction ≤ 40 %. *Minor criterion:* Regional RV akinesia or dyskinesia or dyssynchronous RV contraction and Ratio of RV EDV to BSA ≥ 100 to < 100 mL/m²(male) or ≥ 90 to < 100 mL/m² (female) *or* RV ejection fraction > 40 % to ≤ 45 %. [5] Indication of presence of task force and non-task force criteria (ARVD-typical pattern of fat infiltration and/or non-ischemic LGE) [34], Free text for secondary findings.

Bunck-AC et al. Fortschr Röntgenstr 2019

Arrhythmogene Cardiomyopathy

AGAPLESION
Unsere Werte verbinden

Diagnose & Einstufung:

nicht nur eine rechtsventrikuläre Erkrankung
Identifizierung von linksventrikulär dominanten Formen

Entscheidende Rolle des Kardio-MRT‘s (LGE)

Therapy:

Prognose des linksventrikulären Phänotyps?

Genetik:

meist eine desmosomale Erkrankung

Genetische Untersuchungen sind nur im klinischen Kontext sinnvoll und relevant