DGK Frühjahrstagung, 04.-07. April 2018
Kongresshallen Rosengarten, Mannheim

Niels-Stensen-Kliniken
Marienhospital Osnabrück

Symposium: Rare Diseases: Underdiagnosed and undertreated?

ARVC: Arrhythmogenenic Right Ventricular Cardiomyopathy

Thomas Wichter, MD, FESC
Professor of Medicine (Cardiology)

Klinik Innere Medizin / Kardiologie

Herzzentrum Osnabrück - Bad Rothenfelde

Niels-Stensen-Kliniken
Marienhospital Osnabrück
Germany

Niels-Stensen-Kliniken
Marienhospital Osnabrück

Conflict of Interest - Disclosure

I, Thomas Wichter, DO NOT have a financial interest / arrangement or affiliation with one or more organizations that could be perceived as a real or apparent conflict of interest in the context of the subject of this presentation.

Rare Diseases: ARVC

What is ARVC ?

Be aware of clinical features

- Young, apparently healthy pts
- Ventricular arrhythmias (LBBB pattern)
- Exercise provocable arrhythmias
- High prevalence in athletes
- Family history (ARVC, unexplained SCD)
  - Genetic background (desmosomal proteins)
- Right precordial ECG abnormalities
  - T-wave inversion, QRS prolongation, ε-waves
- RV-enlargement / RV-dysfunction
- LV involvement possible (even dominant)

Niels-Stensen-Kliniken
Marienhospital Osnabrück

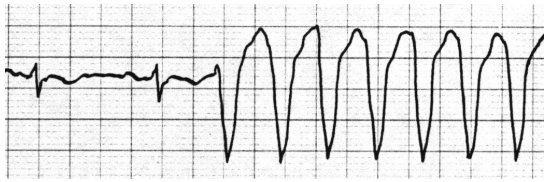

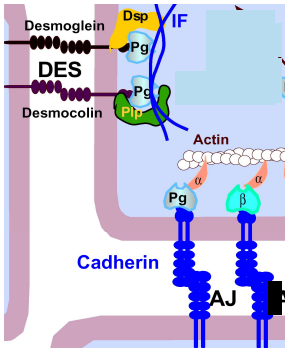



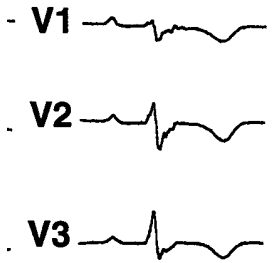

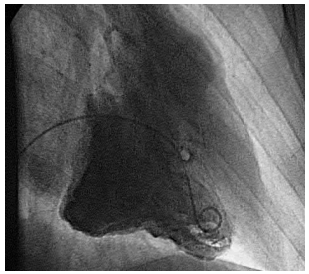

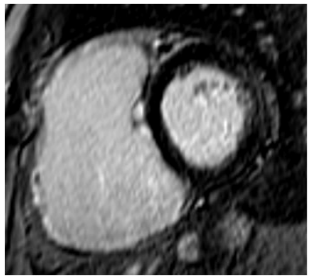

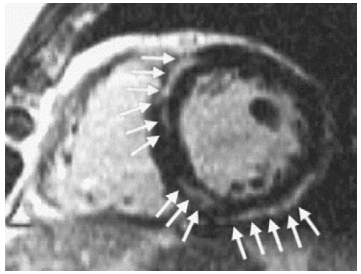

What awareness can do …

Niels-Stensen-Kliniken
Marienhospital Osnabrück

Preparticipation Screening of Athletes

4-fold Reduction of Sudden Death in Athletes in Italy by Disqualification of diagnosed HCM and ARVC pts

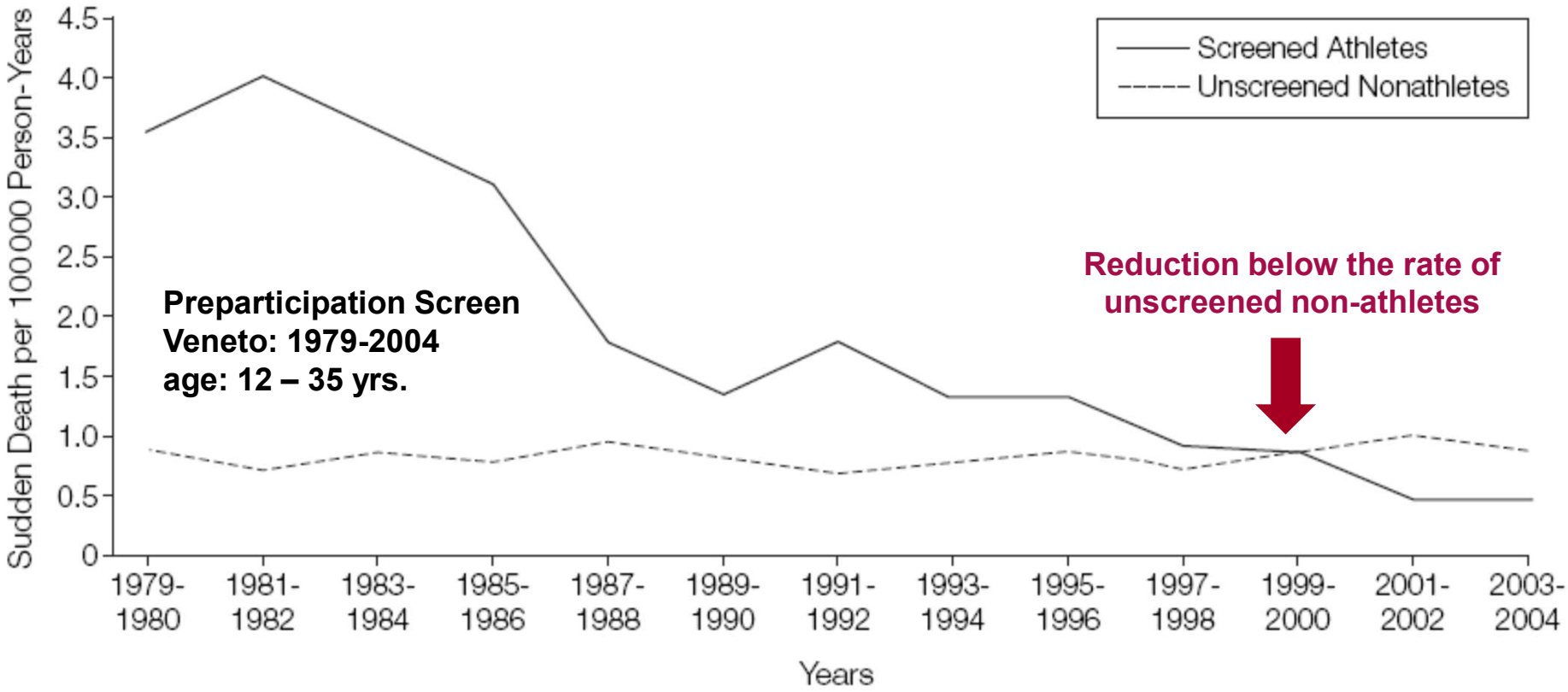

Corrado D et al. JAMA. 2006;296:1593-1601

Epidemiology of ARVC

Niels-Stensen-Kliniken
Marienhospital Osnabrück

- **First descriptions date back to 18th century**
- **Rare disease (1:2000 to 1: 5000, underestimated?)**
- **Regional clustering (genetic reasons; i.e. Veneto)**
- **Difficult, multifactorial diagnosis (integrative approach)**
- **Mild or incomplete disease manifestation (expressivity)**
- **Silent or subclinical mutation carriers (penetrance)**
- **Selection bias results in different ARVC populations (primary vs. tertiary or arrhythmia vs. heart failure vs. genetic centres) with respect to prevalence, expression and prognosis**

Rare Diseases: ARVC

Niels-Stensen-Kliniken
Marienhospital Osnabrück

Underdiagnosed …..?

- … False Negatives (Specificity high, Sensitivity low)
- … Increased risk of sudden death due to undertreatment

Overdiagnosed …..?

- … False Positives (Specificity low, Sensitivity high)
- … Disease „labeling“ (incl. family members)
  potential consequences for social life, sports activity, insurances, etc.
- … Unjustified ICD indications (incl. complications, inappr. shocks)

Misdiagnosed …..?

- … other diseases mimicking ARVC remain unrecognized
  (myocarditis, sarcoidosis, cardiomyopathies, etc.)
- … specific treatment options not applied

Limitations of Evidence

Niels-Stensen-Kliniken
Marienhospital Osnabrück

- Rare disease, no diagnostic gold standard
- Integrated multi-modality diagnostic approach
- Diagnostic Criteria (Internat. Task Force 2010),

  modified to increase accuracy by gain in sensitivity without loss of specificity
  - Wall motion and structure (RV / LV: global + regional)
  - Tissue characterization of walls (histopathology)
  - ECG depolarization (QRS prolongation, epsilon-potential)
  - ECG repolarization (T-wave inversion)
  - Arrhythmias (LBBB-VT, exercise-induced)
  - Genetics / family history (mutations in desmosomal genes)
- Treatment based on personal experience, consensus and individual decisions rather than evidenced data

Diagnostic Criteria of ARVC

International ARVC Task Force (2010)

Niels-Stensen-Kliniken
Marienhospital Osnabrück

EUROPEAN SOCIETY OF CARDIOLOGY®

European Heart Journal
doi:10.1093/eurheartj/ehq025

SPECIAL REPORT

Diagnosis of arrhythmogenic right ventricular cardiomyopathy/dysplasia

Proposed Modification of the Task Force Criteria

Frank I. Marcus[1*] Chair, William J. McKenna[2] Co-Chair, Duane Sherrill[1], Cristina Basso[3], Barbara Bauce[3], David A. Bluemke[4], Hugh Calkins[5], Domenico Corrado[3], Moniek G.P.J. Cox[6], James P. Daubert[7], Guy Fontaine[10], Kathleen Gear[1], Richard Hauer[6], Andrea Nava[3], Michael H. Picard[11], Nikos Protonotarios[13], Jeffrey E. Saffitz[12], Danita M. Yoerger Sanborn[11], Jonathan S. Steinberg[9], Harikrishna Tandri[5], Gaetano Thiene[3], Jeffrey A. Towbin[14], Adalena Tsatsopoulou[13], Thomas Wichter[15], and Wojciech Zareba[8]

Marcus FI et al. Circulation. 2010;121:1533-1541 and Eur Heart J. 2010;31:806-814

Diagnostic Criteria of ARVC

International ARVC Task Force (2010)

Niels-Stensen-Kliniken
Marienhospital Osnabrück

Genetics and Family History

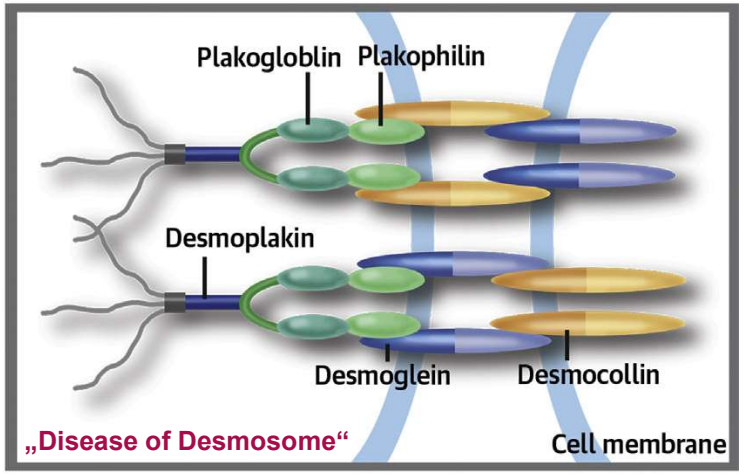

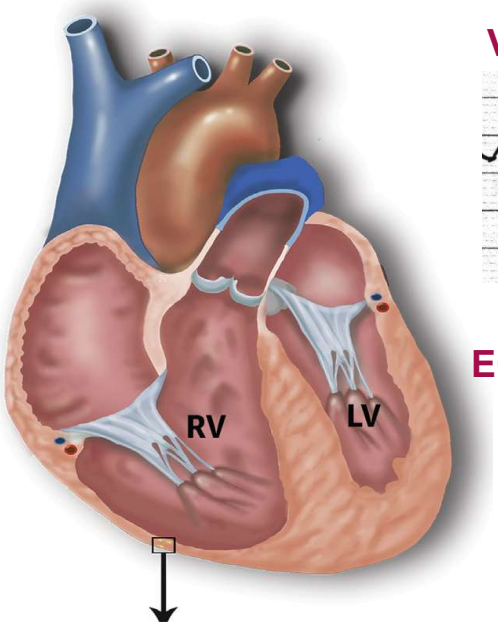

Ventricular Arrhythmias (LBBB-VT)

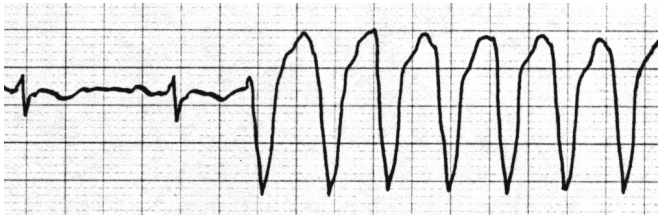

ECG: Depolarization + Repolarization



Tissue Characterization

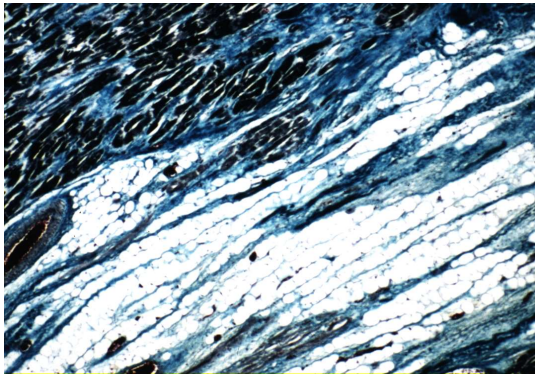

Pathology

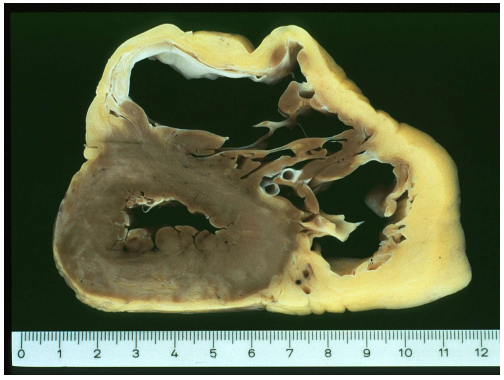

RV-/LV- Wall Motion + Structure

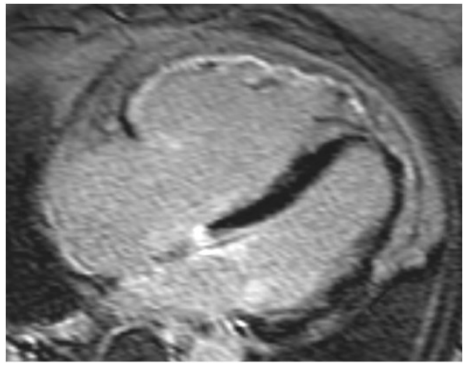

Case-1: Cardiac Arrest

Niels-Stensen-Kliniken
Marienhospital Osnabrück

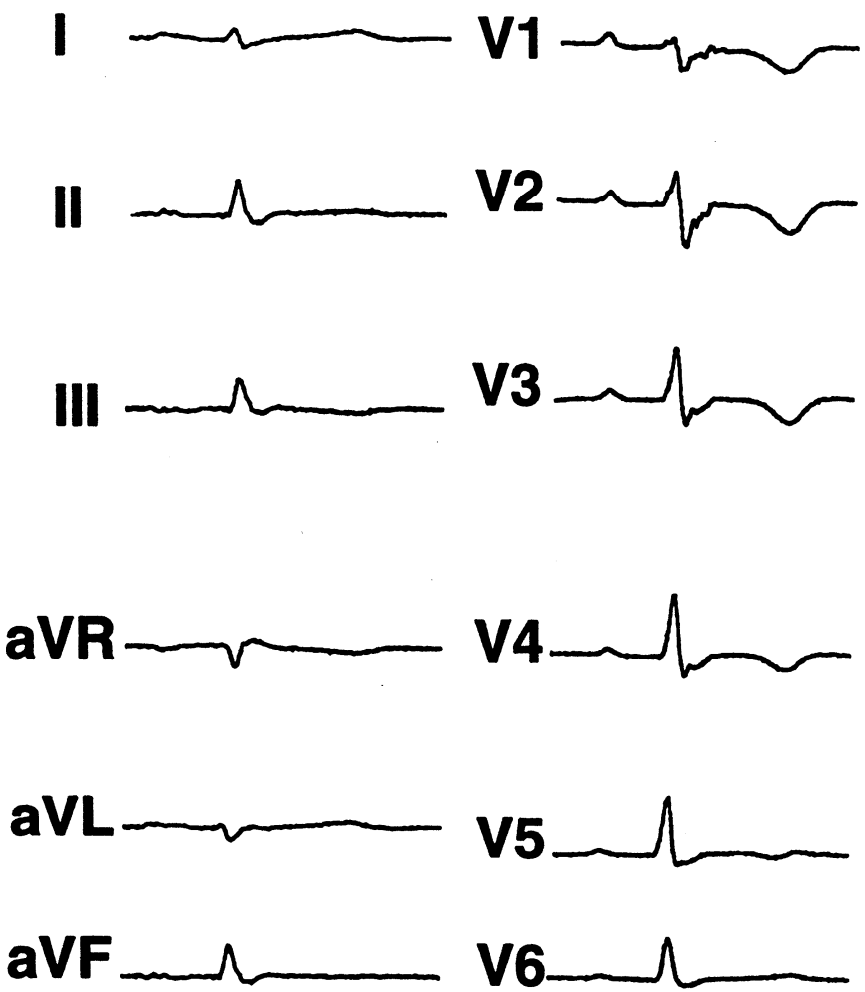

- 31 yr.-old man, athlete
- Cardiac arrest during soccer
- SR after 1° defibrillation
- ROSC and stable rhythm
- Family history of SCD

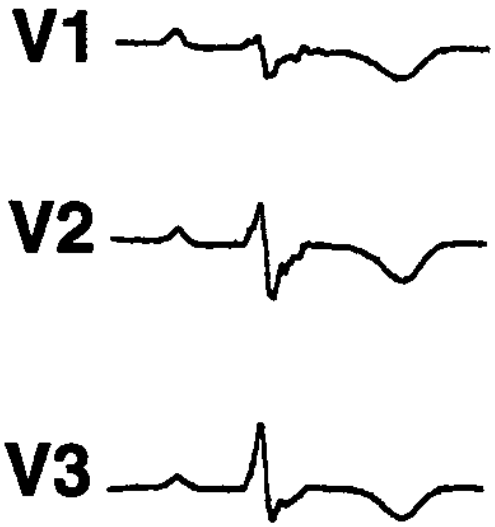

Diagnosis: ARVC

Case-1: Cardiac Arrest

Niels-Stensen-Kliniken
Marienhospital Osnabrück

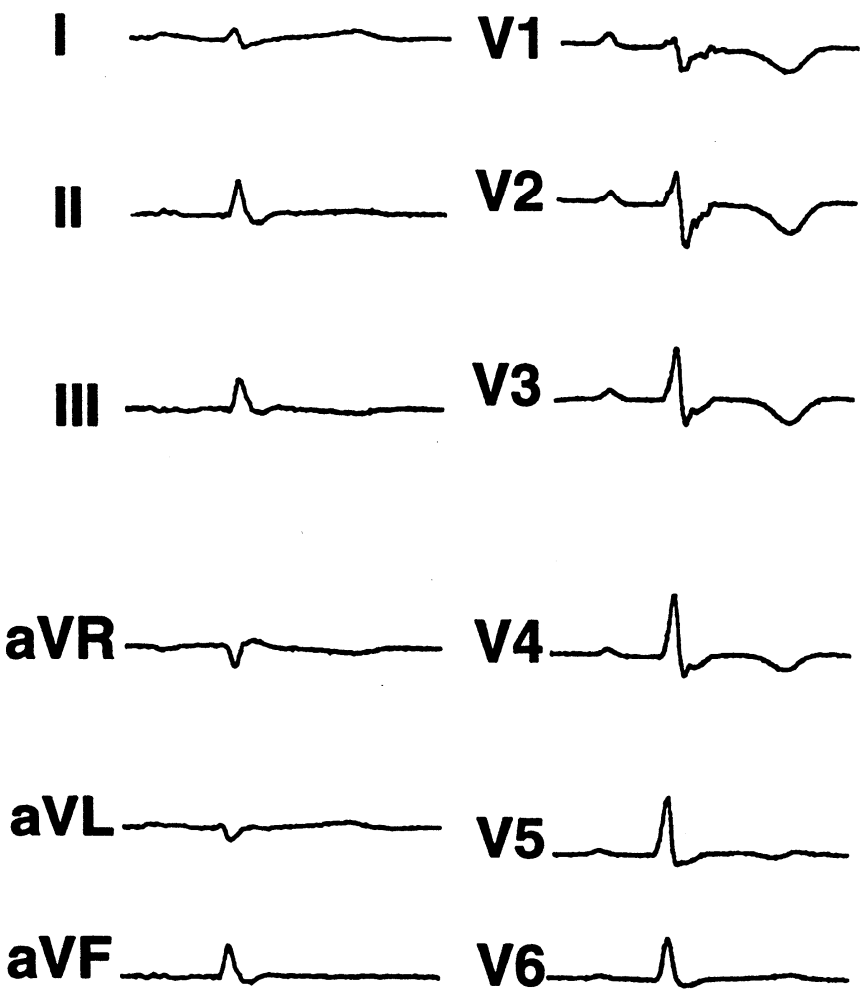

- 31 yr.-old man, athlete
- Cardiac arrest during soccer
- SR after 1° defibrillation
- ROSC and stable rhythm
- Family history of SCD

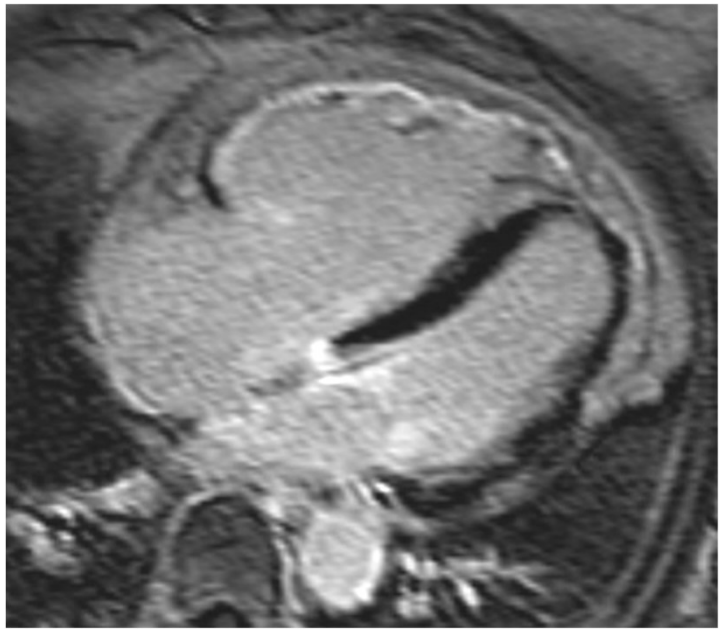

Diagnosis: ARVC

Case-1: Cardiac Arrest

Niels-Stensen-Kliniken
Marienhospital Osnabrück

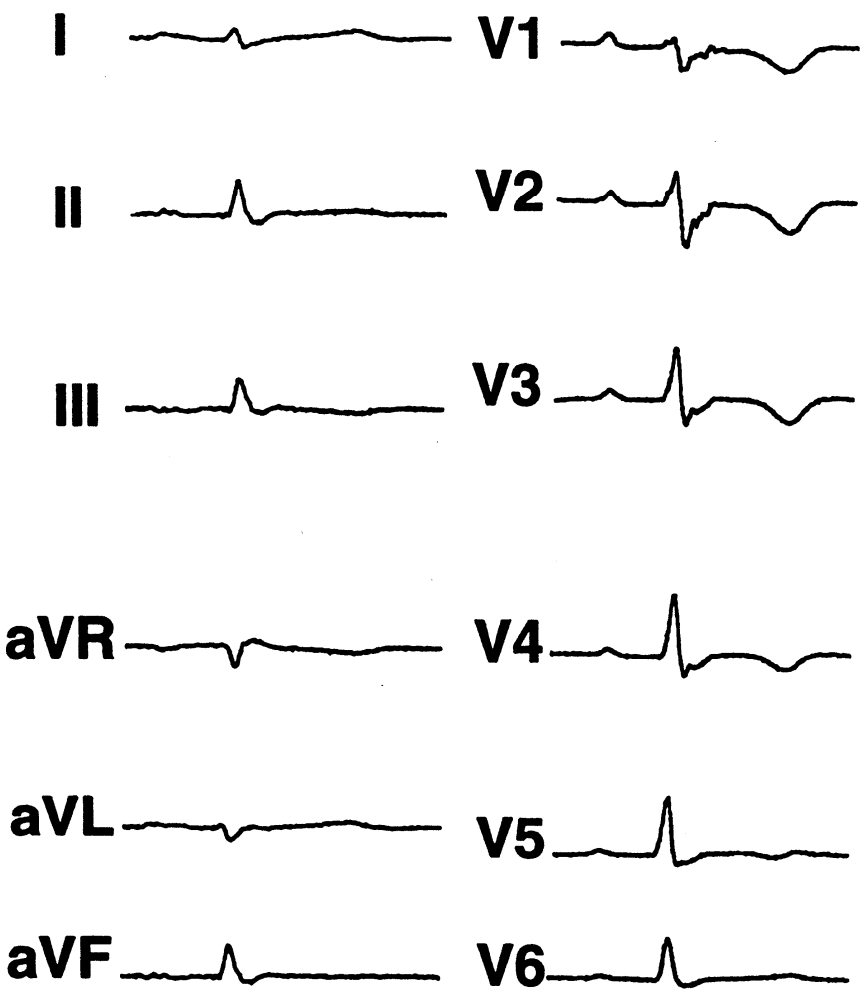

- 31 yr.-old man, athlete
- Cardiac arrest during soccer
- SR after 1° defibrillation
- ROSC and stable rhythm
- Family history of SCD

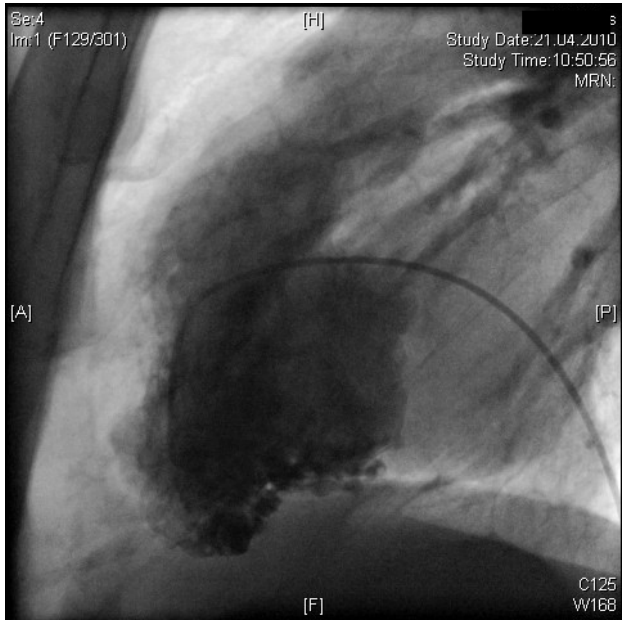

Diagnosis: ARVC

Rare Diseases: ARVC

Niels-Stensen-Kliniken
Marienhospital Osnabrück

Reassess: Is it really ARVC? Or is it rather … ?

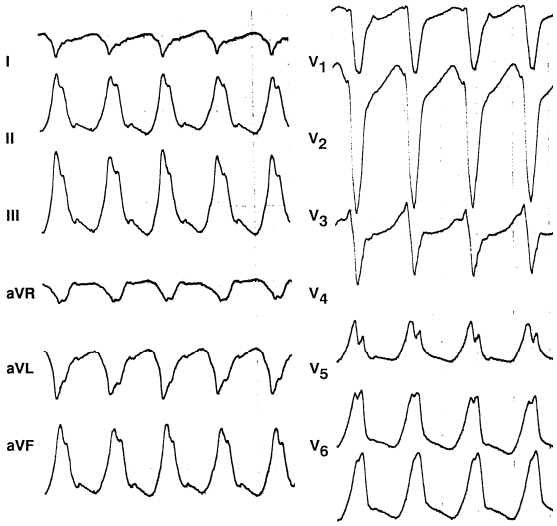

Idiopathic RVO-VT

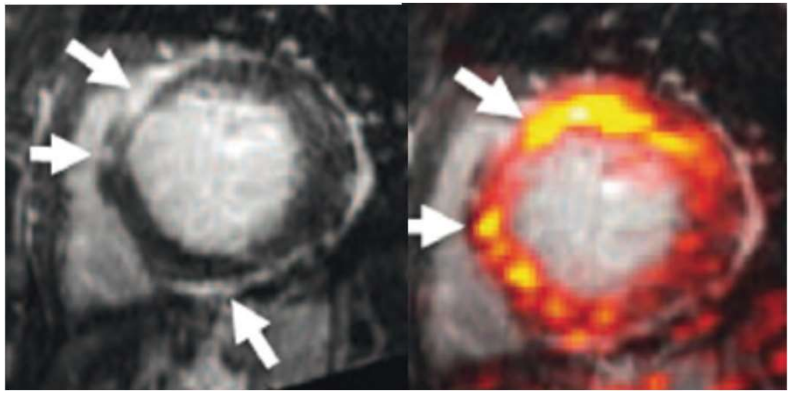

Cardiac Sarcoidosis

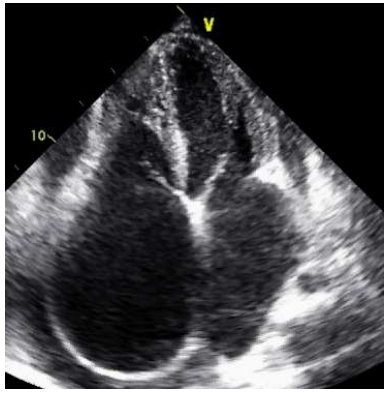

Restrictive CM

Make the correct diagnosis
for specific therapy !

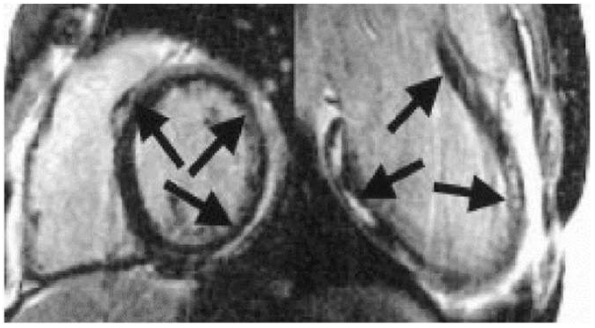

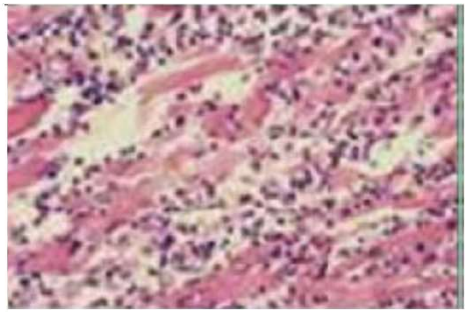

Myocarditis (acute / chronic)

Making the Correct Diagnosis

Niels-Stensen-Kliniken
Marienhospital Osnabrück

- **Detailed diagnostic evaluation** (multi-modality approach)
- **Appropriate test protocols for ARVC diagnosis**

  ECG speed and filters, Angio projections, Echo views on RV,
  MRI protocol and sequences, target-directed biopsy, 3D EP-Mapping
- **Avoid bias when indicating tests** (question triggers answer)
- **Expert reading and interpretation of findings**
- **Genetic testing for identification of affected relatives**

  Confirmatory testing controversial (diagnosis and risk stratification)
  Proband: Negative psychological + social impact may outweigh clinical value
  Family: Cascade screening helps to identify subjects at risk
- **Balanced and experienced clinical evaluation**

  Counselling and recommendations for management of ARVC (incl. families)

Niels-Stensen-Kliniken
Marienhospital Osnabrück

Arrhythmias in ARVC:
Unique VT substrate

- **Familial, genetic basis** (desmosomal proteins)
- **Broad spectrum of clinical VA** (PVC, syncope, VT, VF)
- **Phasic clinical stages** (natural history)
- **Exercise modification** (penetrance, expression, aggravation)
- **Progressive** (exercise, competitive sports, inflammation, etc.)
- **Multifocal** (RV, LV)
- **Predilection areas** (RVOT, apex, RV-inflow)
- **Pleomorphic** (multiple VT morphologies, mostly LBBB)
- **Epicardial location** (mapping + ablation)

Niels-Stensen-Kliniken
Marienhospital Osnabrück

ECG Diagnostics

Most important screening tool in ARVC !

- **Inverted T-waves** in right precordial leads (V_1-V_3)
  - Normal in children <14 yrs., only 1% in normal older individuals
  - 60-95% prevalence in ARVC (major diagnostic criterion)
  - Near 100% sensitivity when combined with LBBB-VT
  - Extent relates to degree of RV involvement in ARVC
- **QRS prolongation** in right precordial leads (V_1-V_3)
  - Conduction delay over RV (arrhythmogenic substrate)
  - QRS >110 ms, S-wave >55 ms are sensitive markers of ARVC
- **Epsilon wave (potential)** in right precordial leads (V_1-V_3)
  - Low amplitude signal after the end of QRS
  - Mainly present in severe manifestations of ARVC
  - High interobserver variability (no added value without other ARVC criteria)

ECG: Epsilon-Potential

Epsilon wave after the end of QRS in V_{1-3}, separated from QRS by isoelectrical interval

Niels-Stensen-Kliniken
Marienhospital Osnabrück

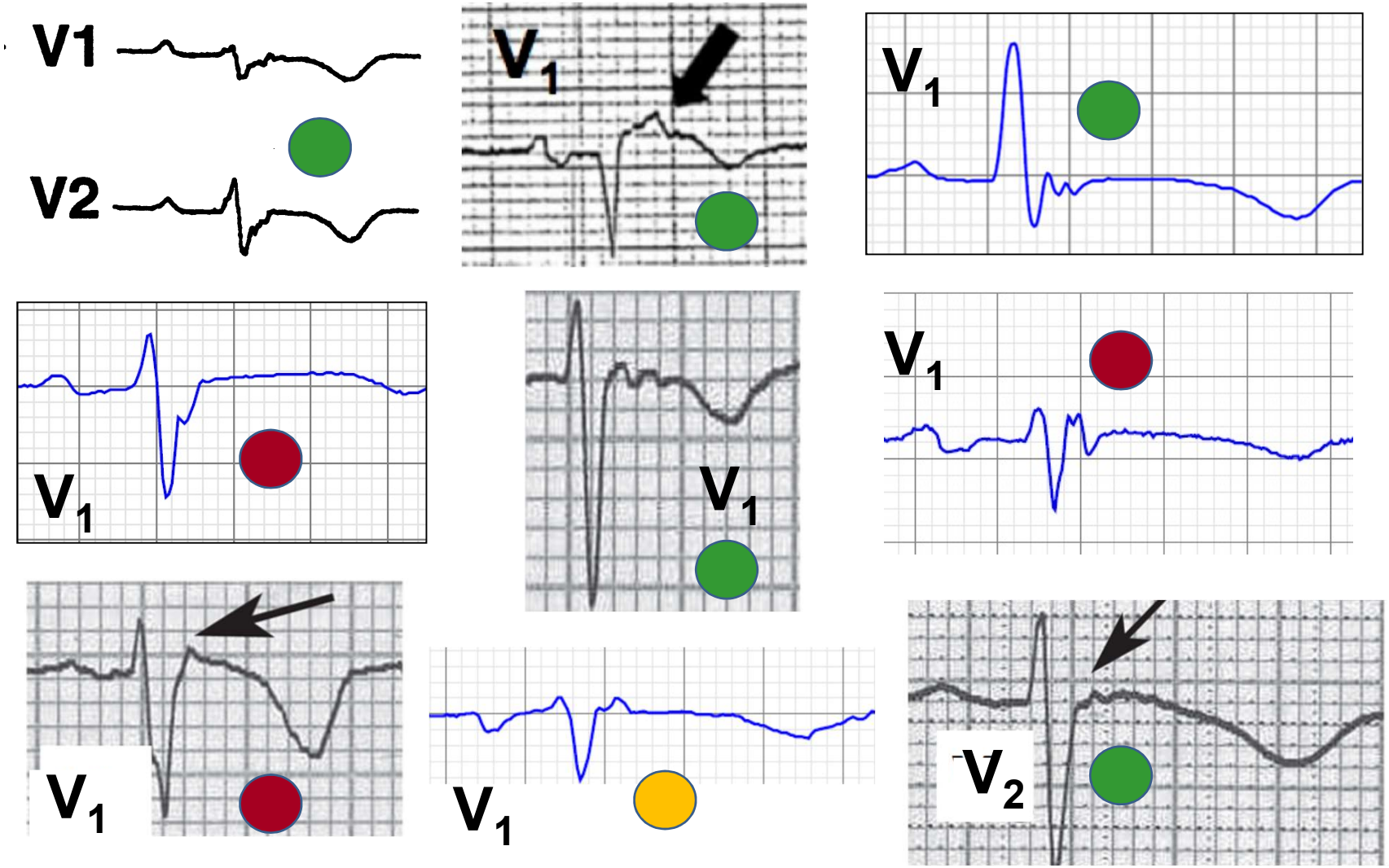

Platonov PG, …, Wichter T,…, et al. Heart Rhythm.2015.

ECG: Epsilon-Potential

Main message: diagnostic impact was low (no added value).
Caution in assessment when pts do not otherwise fulfill criteria

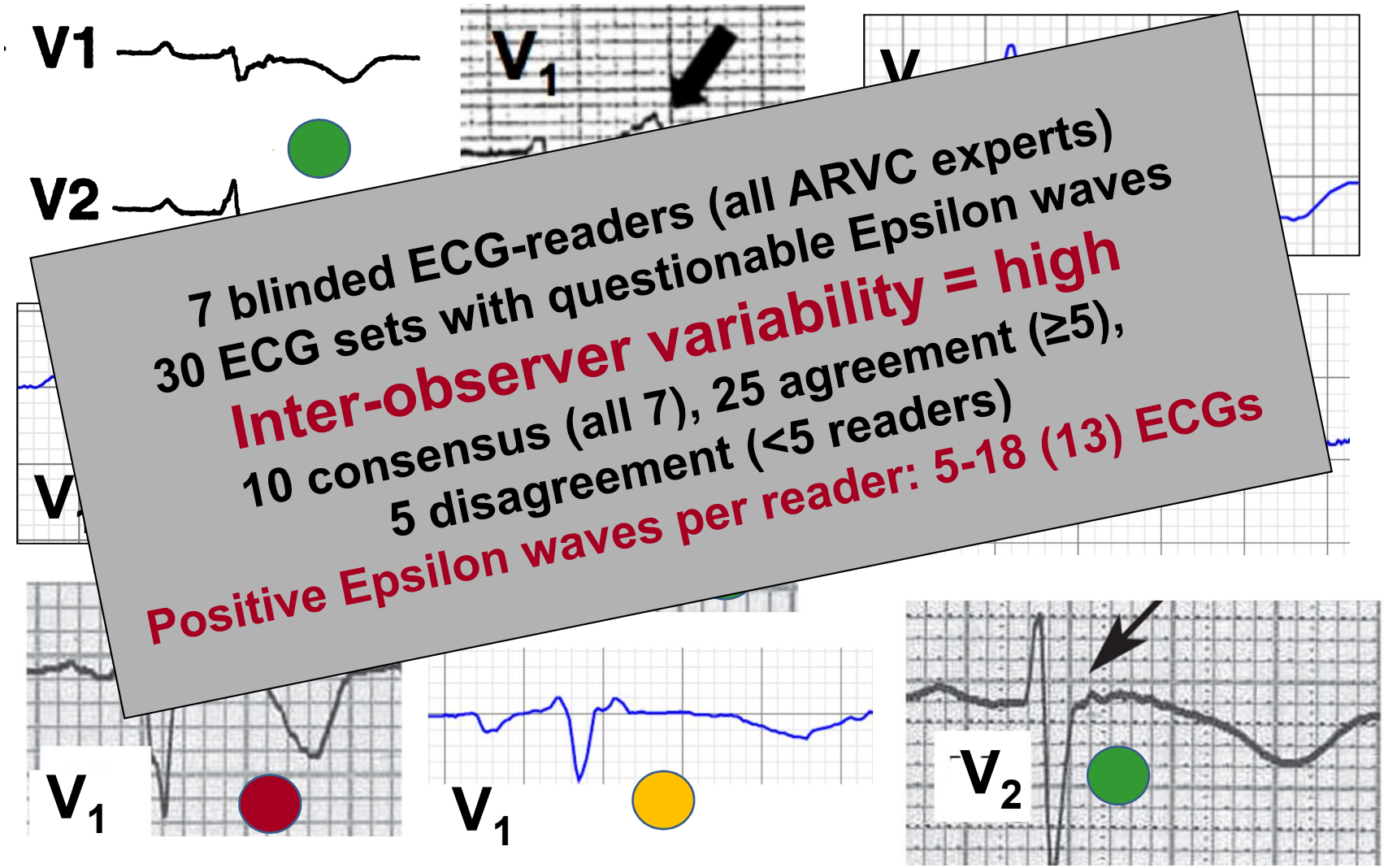

7 blinded ECG-readers (all ARVC experts)
30 ECG sets with questionable Epsilon waves
Inter-observer variability = high
10 consensus (all 7), 25 agreement (≥5),
5 disagreement (<5 readers)
Positive Epsilon waves per reader: 5-18 (13) ECGs

Platonov PG, …, Wichter T,…, et al. Heart Rhythm.2015.

Cardiac Imaging

Niels-Stensen-Kliniken
Marienhospital Osnabrück

- **RV evaluation by imaging remains difficult**
  - Despite enormous improvement in imaging technology
  - Complex RV structure, shape and wall motion (non-symmetrical)
- **MRI depicts wall structure, motion + tissue**
  - Fatty infiltration alone is not a sufficient criterion
  - Fibrofatty replacement + abnormal regional wall motion = diagnostic
- **Appropriate imaging protocols and expert reading**
  - Multimodal diagnostic approach
  - Standardized imaging protocols and quantitative analysis
  - Interpretation by experts in imaging and ARVC
- **High degree of inter-observer variability**
  - Incorrect MRI interpretation is a frequent cause of overdiagnosing !

Ask Questions, get Answers

Niels-Stensen-Kliniken
Marienhospital Osnabrück

- Dx: Idiopathic RV Outflow-Tract Tachycardia (RVO-VT)
- Q: „Clinical suspect of ARVC. Fibrofatty replacement of myocardium? Wall motion abnormalities?“
- A: „Findings well compatible with ARVC, but nonspecific: prominent trabeculation, epicardial fat and fibrosis, mainly over RV free wall“

- Dx: ARVC with LV involvement
- Q: „Unexplained syncope and palpitations. Structural abnormalities of the heart?“
- A: „Nonspecific diffuse myocardial damage, DD: mild dilative CMP (DCM), chronic myocarditis“

Genetic Background + Testing

Niels-Stensen-Kliniken
Marienhospital Osnabrück

- Gene mutations in 60-70% of ARVC
- Desmosomal genes affected
  - Cell contact, adhesion and signal transduction
- Autosomal-dominant genetic trait
  - Reduced penetrance (silent gene carriers)
  - Variable expressivity (disease manifestation and severity)
  - Modifier genes and exogenic factors
  - Digenic or compound mutations (5-20%) may impact severity
  - Genetic polymorphism (non-specific): up to 20% of normal controls
- Genetic counseling mandatory
- Genetic testing controversial
  - Confirmatory testing rarely impacting diagnosis + risk assessment
  - Proband: usually no consequence or added benefit, but allows …
  - … Cascade screening: to identify / exclude gene-affected relatives

Rare Diseases: ARVC

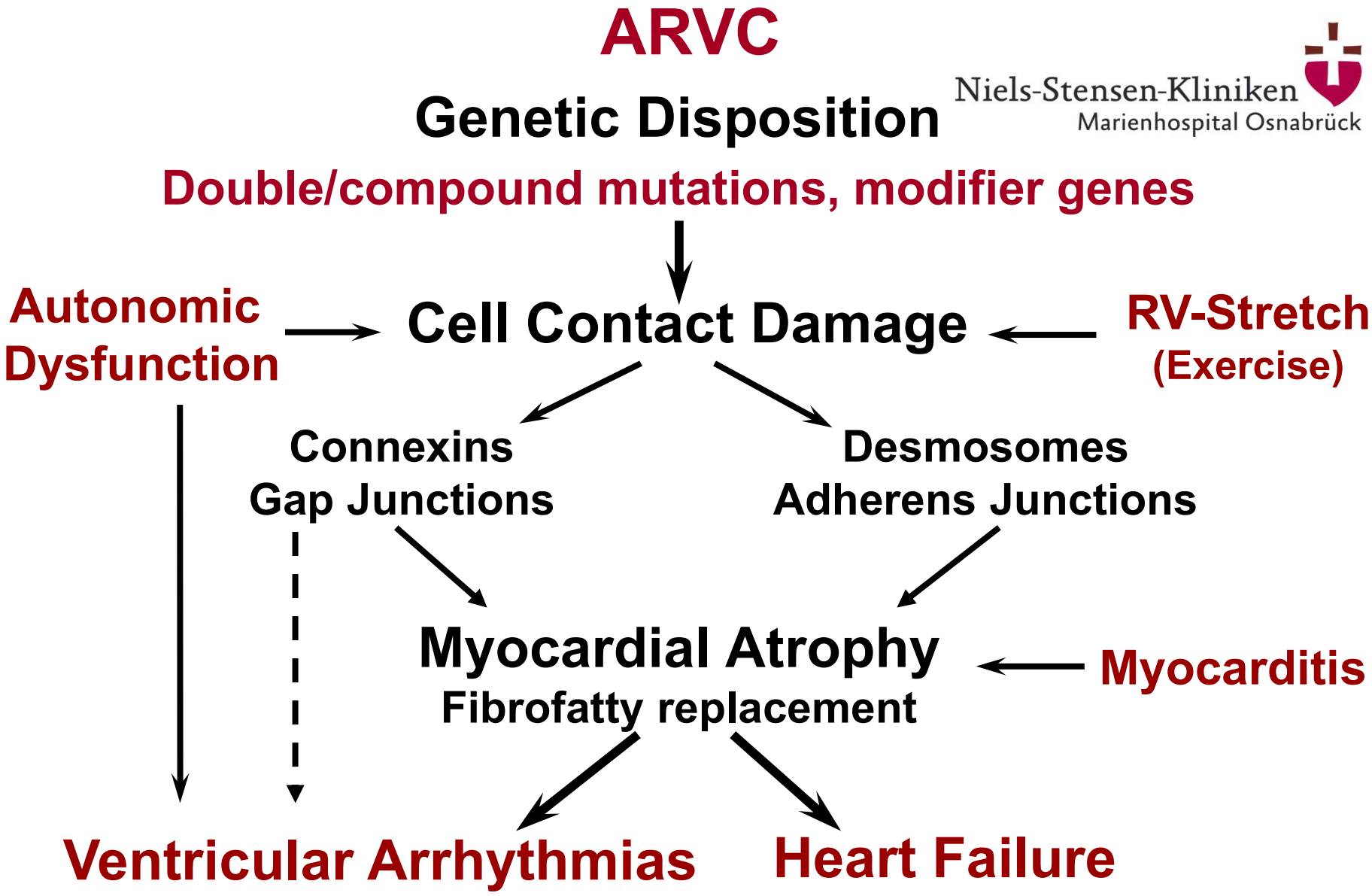

Wichter T et al. in Marcus FI, Nava A, Thiene G (eds.), Springer Verlag. 2008, page 147

Natural Course of ARVC

Niels-Stensen-Kliniken
Marienhospital Osnabrück

- **Risk of VF or fast VT: early (concealed) phase**
  (arrhythmias may precede morphological abnormalities)
- **Recurrent monomorphic VT: overt phase**
- **Chronic biventricular heart failure: end-stage**

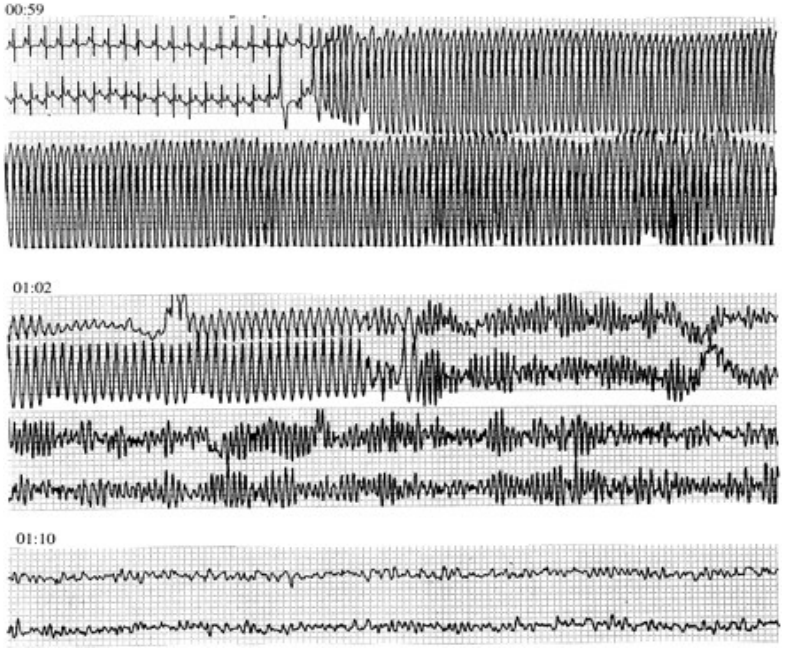

Aziz et al., Circulation. 2000;101;825-827

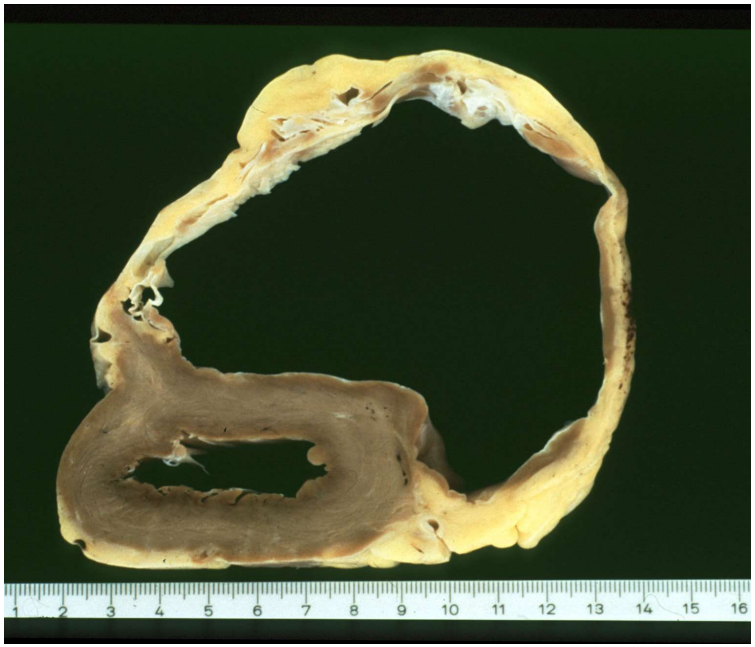

Wichter T et al., 2005

Case-2: Asymptomatic nsVT

male, age 14

Niels-Stensen-Kliniken
Marienhospital Osnabrück

- **Symptom:** presyncope (vasovagal?)
- **Sports:** competitive (football)
- **Family history:** 1 questionable case
- **Genetic test:** nonspecific, Desmoplakin polymorphism
- **ECG:** normal 12-lead and SAECG negative T in V1-V2
- **Exercise Test:** 1x nsVT (5 sec, 165 bpm)
- **Echo:** mild LV dilatation, normal RV
- **MRI:** normal RV + LV, no fat, no LGE
- **EP-Study:** normal, no WPW, no SVT or VT/VF inducible

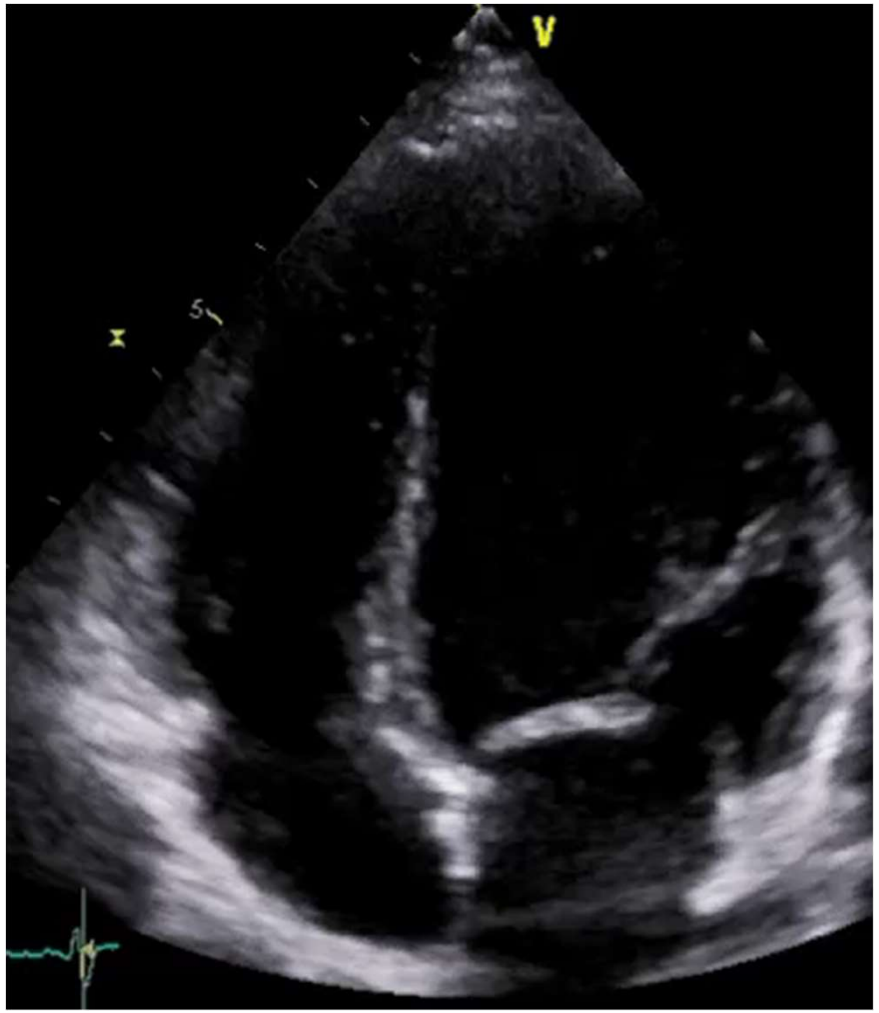

Case-2: Asymptomatic nsVT

male, age 14

Niels-Stensen-Kliniken
Marienhospital Osnabrück

- **Symptom:** presyncope (vasovagal?)
- **Sports:** competitive (football)
- **Family history:** 1 questionable case
- **Genetic test:** nonspecific, Desmoplakin polymorphism
- **ECG:** normal 12-lead and SA
  negative T in V1-V2
- **Exercise T**
- **E**
- **no LGE**
- **E**
  nal,
  no W **SVT or VT/VF inducible**

What risk ?

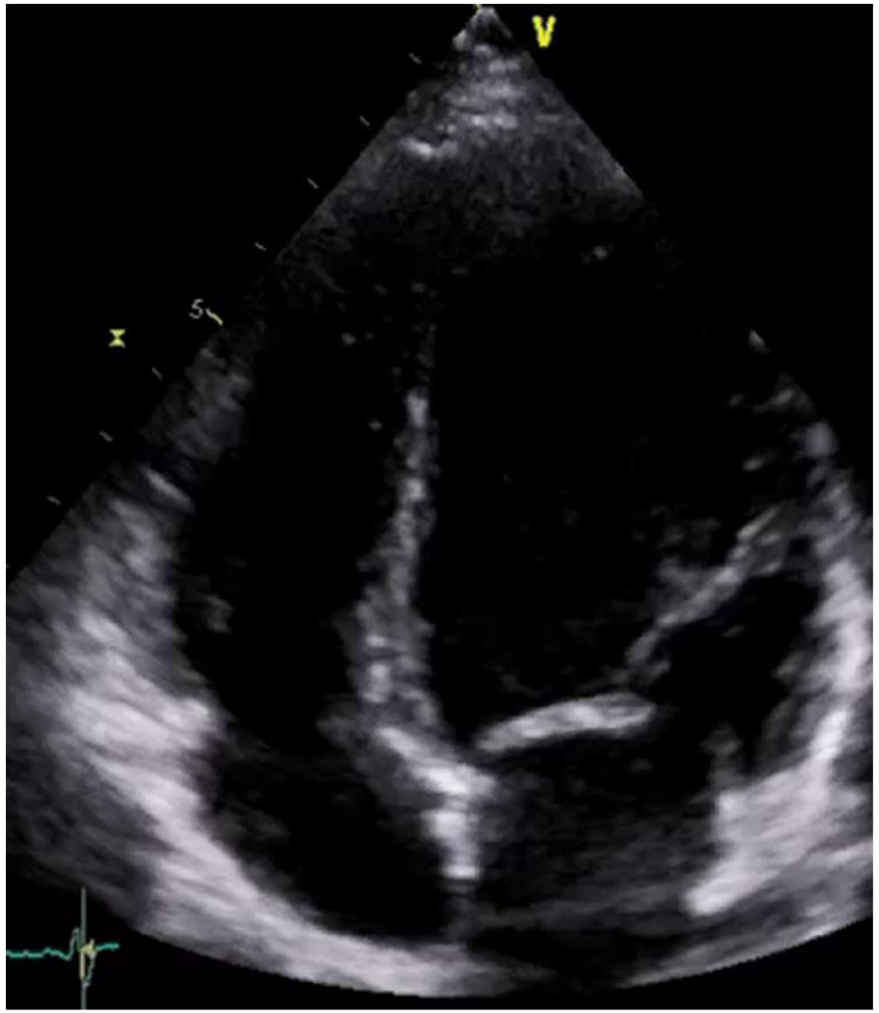

Case-2: Asymptomatic nsVT

Niels-Stensen-Kliniken
Marienhospital Osnabrück

nsVT 5 sec (165 bpm, LBBB, inferior axis)
asymptomatic during treadmill stress test

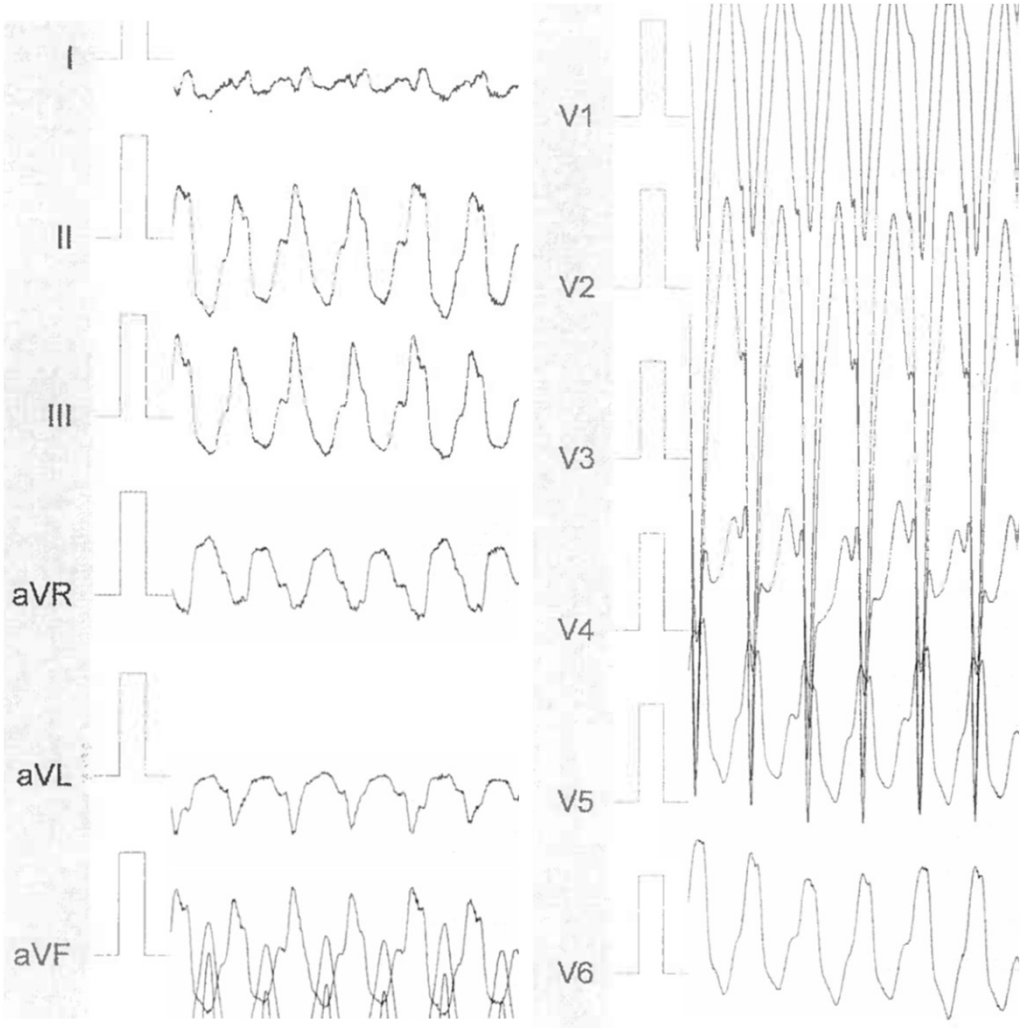

Resting ECG during SR

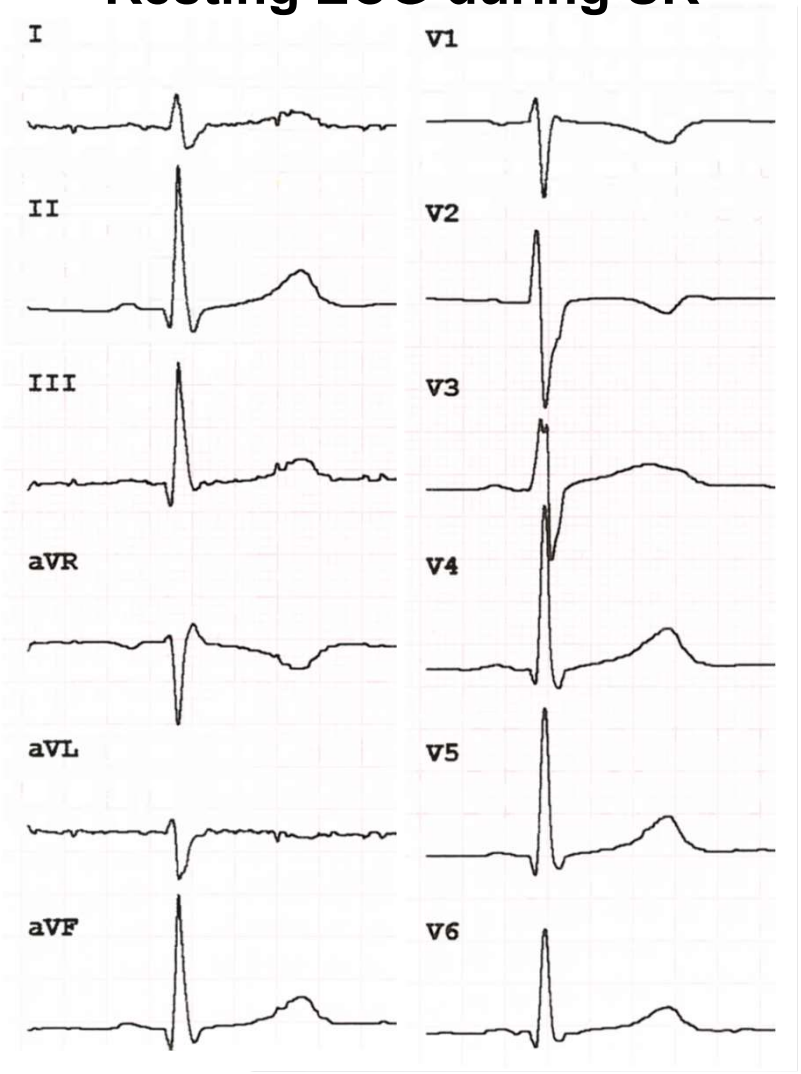

Risk Stratification in ARVC

Role of Syncope, nsVT, Family History

Niels-Stensen-Kliniken
Marienhospital Osnabrück

ICD intervention-free survival in prim. prevention ICD cohort

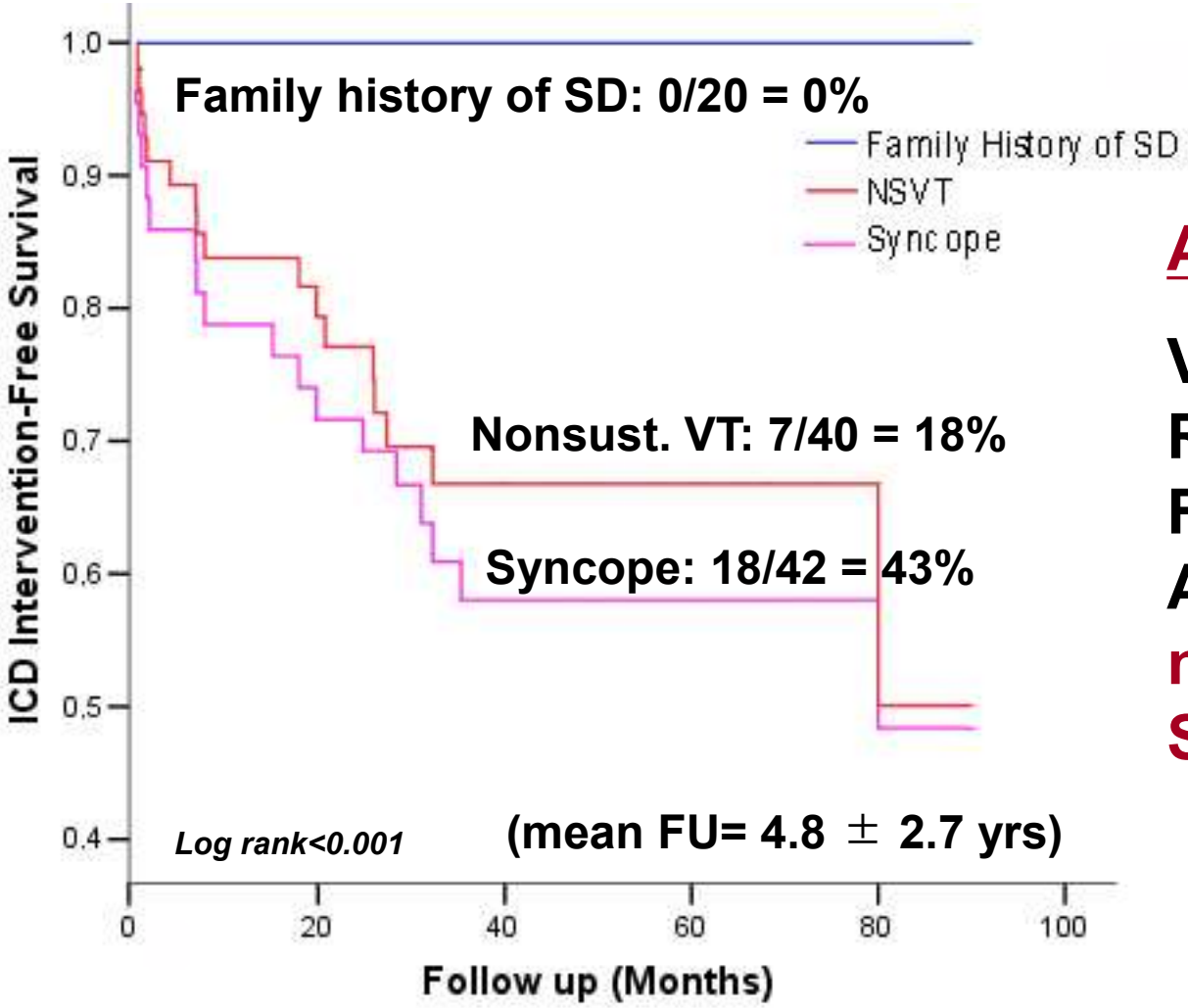

Appropriate ICD-Tx:

VT at PVS:	p = 0.98
RV ↓ (diffuse):	p = 0.84
Family Hx:	p = 0.14
Age < 35:	p = 0.07
nsVT:	p = 0.03
Syncope:	p = 0.008

DARVIN-2 Registry.
Corrado D et al.
Circulation. 2010;122:1144

Niels-Stensen-Kliniken
Marienhospital Osnabrück

Case-2: Asymptomatic nsVT

male, athlete, age 14

- **Symptom:** presyncope (vasovagal?)
- **Sports:** competitive (football)
- **Family history:** 1 questionable case
- **Genetic test:** nonspecific, Desmoplakin polymorphism
- **ECG:** normal 12-lead and SAECG negative T in V1-V2
- **Exercise Test:** 1x nsVT (5 sec, 165 bpm)
- **Echo:** mild LV dilatation, normal RV
- **MRI:** normal RV + LV, no fat, no LGE
- **EP-Study:** normal, no WPW, no SVT or VT/VF inducible

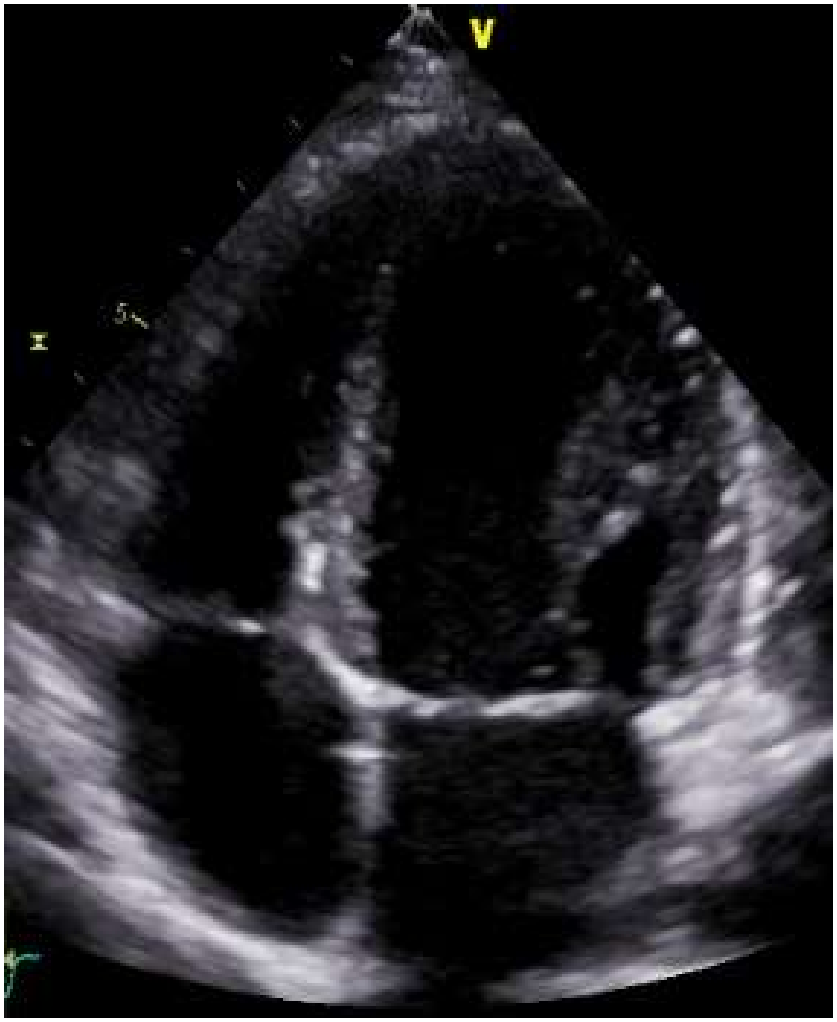

Rare Diseases: ARVC

Case-2: Asymptomatic nsVT

male, athlete, age 14

Niels-Stensen-Kliniken
Marienhospital Osnabrück

- **Symptom:** presync
- **Sports:**
- **Fa**
- **al 12-lead and SAECG**
  T in V1-V2
- **Exercise Test:** 1x nsVT (5 sec, 165 bpm)
- **Echo:** mild LV dilatation, normal RV
- **MRI:** normal RV + LV, no fat, no LGE
- **EP-Study:** normal,
  no WPW, no SVT or VT/VF inducible

Defibrillator ?

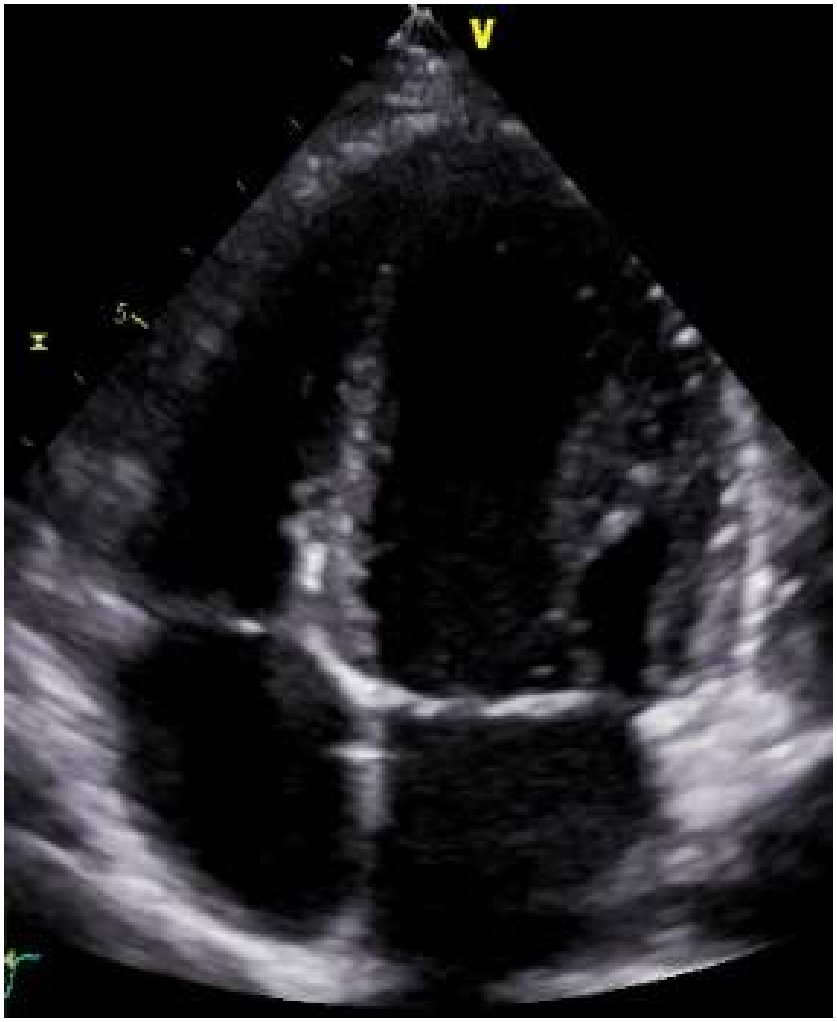

Case-2: Asymptomatic nsVT

Niels-Stensen-Kliniken
Marienhospital Osnabrück

Clinically relevant questions:

- Is this ARVC (no structural disease detected) ?
- Was genetic testing useful ?
- Should this 14 yr-old boy be labelled with a disease ?
  - Issues of psychology, quality of life, insurances, etc.
- What is the prognosis ?

My personal (!) decision:

Low-dose beta-blockers
Recreational sports o.k. (non-competitive!)
Watchful waiting and reevaluation
Final diagnosis left open

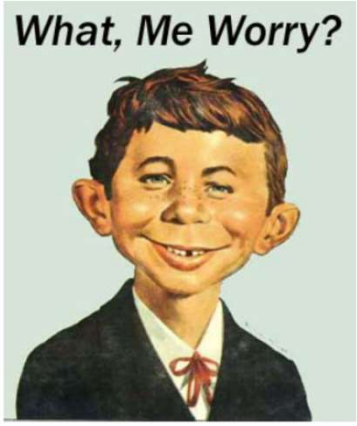

Management of ARVC

Niels-Stensen-Kliniken
Marienhospital Osnabrück

European Heart Journal Advance Access published July 27, 2015

European Heart Journal
doi:10.1093/eurheartj/ehv162

CURRENT OPINION

Treatment of arrhythmogenic right ventricular cardiomyopathy/dysplasia: an international task force consensus statement

Domenico Corrado[1*], Thomas Wichter[2], Mark S. Link[3], Richard Hauer[4], Frank Marchlinski[5], Aris Anastasakis[6], Barbara Bauce[1], Cristina Basso[1], Corinna Brunckhorst[7], Adalena Tsatsopoulou[8], Harikrishna Tandri[9], Matthias Paul[10], Christian Schmied[7], Antonio Pelliccia[11], Firat Duru[7], Nikos Protonotarios[8], NA Mark Estes III[3], William J. McKenna[12], Gaetano Thiene[1], Frank I. Marcus[13], and Hugh Calkins[9]

Eur Heart J. 2015;36: online July 27

Rare Diseases: ARVC

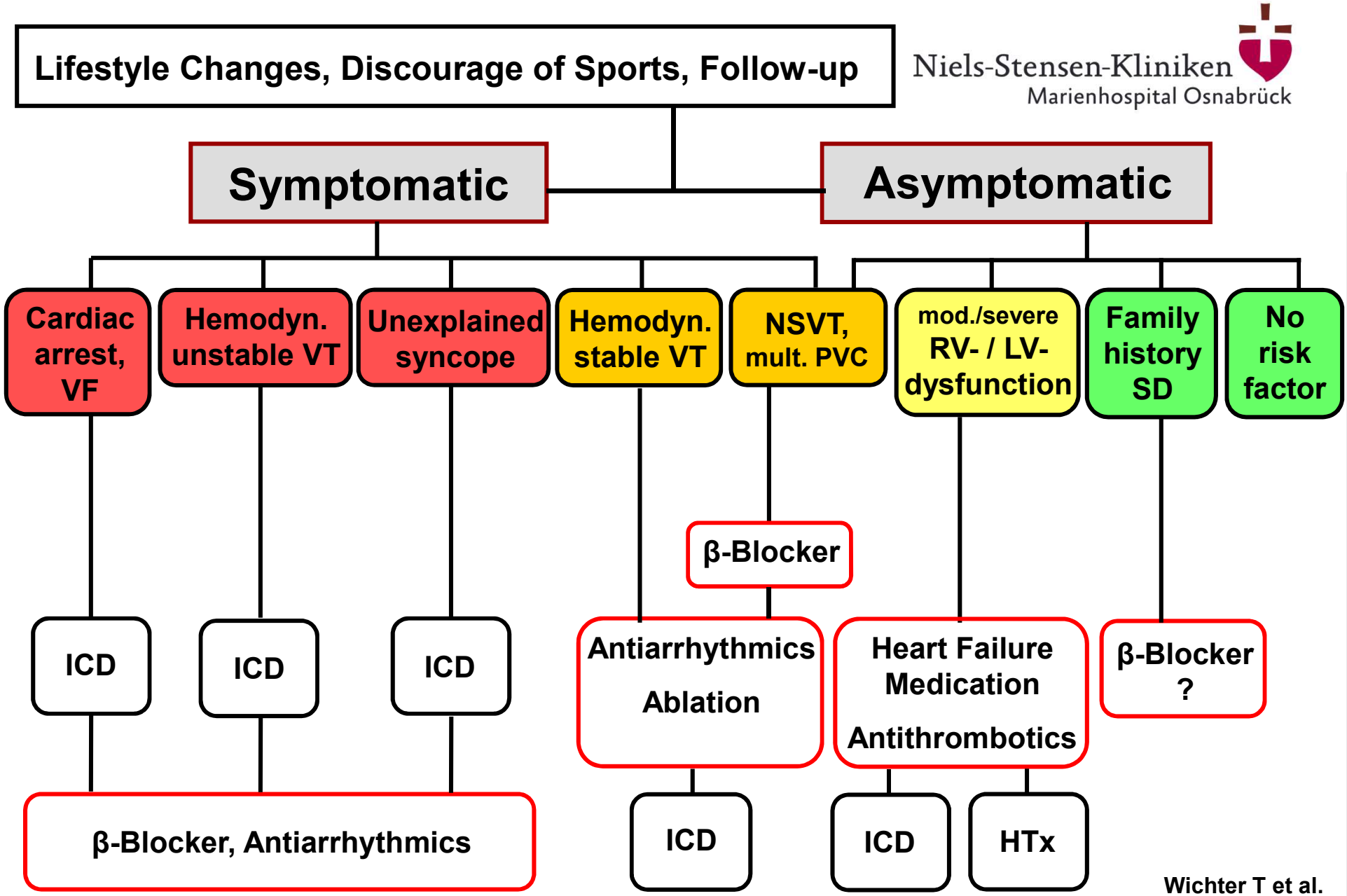

Wichter T et al.
Kardiologe 2014

Risk Stratification in ARVC

ICD Indication in ARVC

Niels-Stensen-Kliniken
Marienhospital Osnabrück

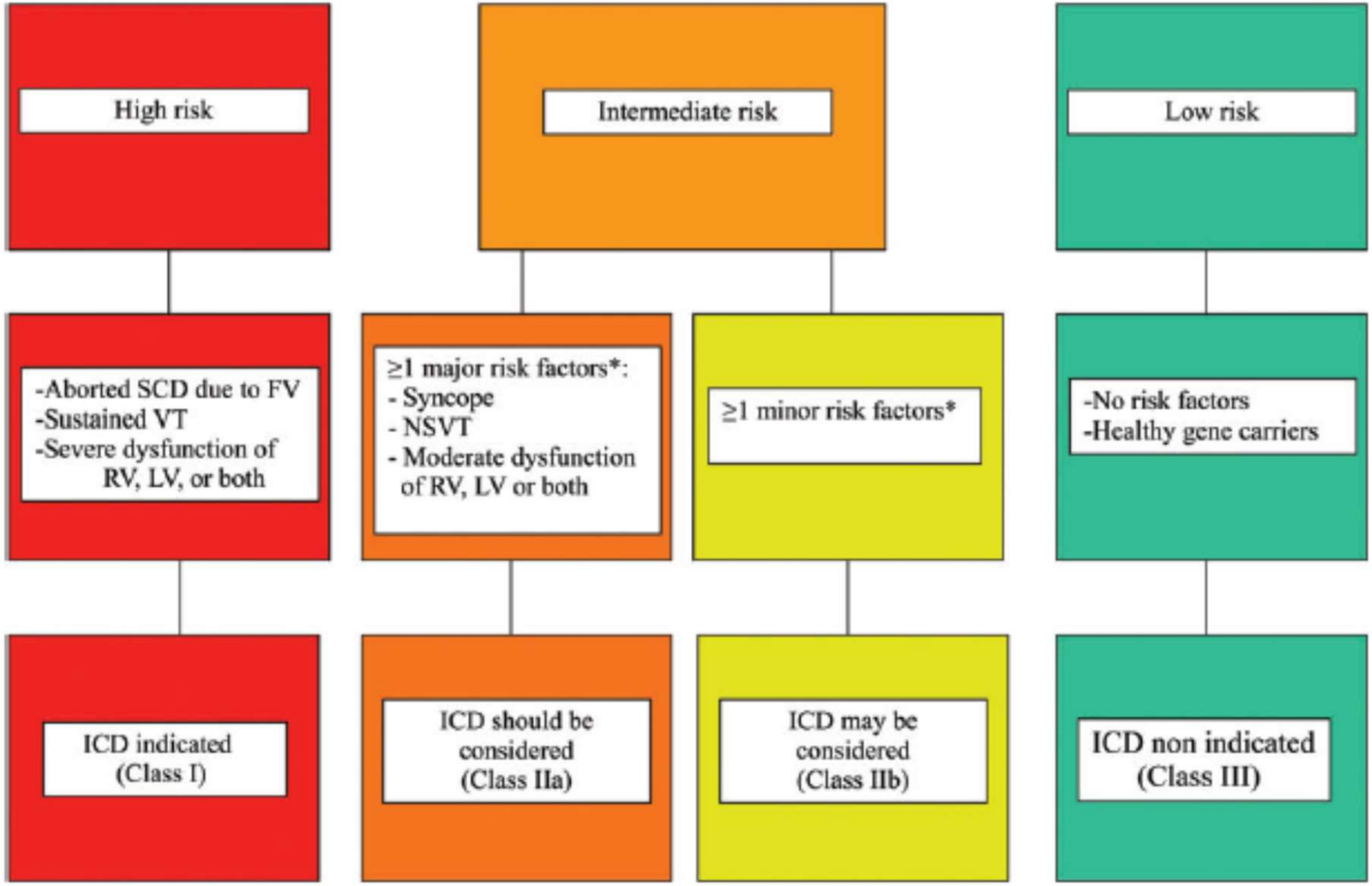

Corrado D, Wichter T, et al. Eur Heart J. 2015 and Circulation 2015; online July 27, 2015

Provocative Statement

Niels-Stensen-Kliniken
Marienhospital Osnabrück

- **We should be the patient‘s „medical lawyer“**
  - Correct diagnosis, best counseling, appropriate therapy
  - Personalized medicine according to data and experience
  - Prevention of sudden death
  - Improvement in quality of life
  - Avoid overdiagnosing with psychological + social impact

- **We should not become our own „defence lawyer“**
  - Decisions and counseling not driven by medicolegal aspects
  - Doctor‘s peace of conscience
  - Fear of malpractice lawsuits
  - „Treat the patient, not ourselves“ (by pseudo-safety decisions)

Take-Home Messages

Niels-Stensen-Kliniken
Marienhospital Osnabrück

- Be aware of ARVC signs + symptoms („could it be ARVC?“)
- Avoid underdiagnosing and undertreatment (SCD risk)
- Perform detailed diagnostic examination
- Assure expert reading + interpretation of tests
- Make the correct diagnosis (Task Force Criteria 2010)
- Think twice before you recommend genetic testing
  - Clear consequences, integration into clinical management
- Reassure ARVC, check for DD („is it really ARVC?“)
- Avoid overdiagnosing („false labeling“ and ICD „overtreatment“)
- Individual, personalized treatment decisions

DGK Frühjahrstagung, 04.-07. April 2018
Kongresshallen Rosengarten, Mannheim

Niels-Stensen-Kliniken
Marienhospital Osnabrück

Symposium: Rare Diseases: Underdiagnosed and undertreated?

ARVC: Arrhythmogenenic Right Ventricular Cardiomyopathy

Thomas Wichter, MD, FESC
Professor of Medicine (Cardiology)

Klinik Innere Medizin / Kardiologie

Herzzentrum Osnabrück - Bad Rothenfelde

Niels-Stensen-Kliniken
Marienhospital Osnabrück
Germany